



REVISTA BRASILEIRA DE ANESTESIOLOGIA

Official Publication of the Brazilian Society of Anesthesiology
www.sba.com.br



CLINICAL INFORMATION

Transient unilateral combined paresis of the hypoglossal nerve and lingual nerve following intubation anesthesia

Hulya Ulusoy*, Ahmet Besir, Bahanur Cekic, Muge Kosucu, Sukran Geze

Department of Anesthesiology and Critical Care, Faculty of Medicine, Karadeniz Technical University, Trabzon, Turkey

Received 8 November 2012; accepted 14 December 2012

Available online 11 October 2013

KEYWORDS

Hypoglossal paralysis;
Lingual paralysis;
Intubation anesthesia

Abstract Nerve damage may occur in the pharyngolaryngeal region during general anesthesia. The most frequently injured nerves are the hypoglossal, lingual and recurrent laryngeal. These injuries may arise in association with several factors, such as laryngoscopy, endotracheal intubation and tube insertion, cuff pressure, mask ventilation, the triple airway maneuver, the oropharyngeal airway, manner of intubation tube insertion, head and neck position and aspiration.

Nerve injuries in this region may take the form of an isolated single nerve or of paresis of two nerves together in the form of hypoglossal and recurrent laryngeal nerve palsy (Tapia's syndrome). However, combined injury of the lingual and hypoglossal nerves following intubation anesthesia is a much rarer condition. The risk of this damage can be reduced with precautionary measures. We describe a case of combined unilateral nervus hypoglossus and nervus lingualis paresis developing after intubation anesthesia.

© 2013 Sociedade Brasileira de Anestesiologia. Published by Elsevier Editora Ltda. All rights reserved.

Background and objectives

Within the framework of general anesthesia (GA), postoperative airway complications do not have a negative impact on patient comfort. Unilateral or bilateral nerve damage occupies an important place among these complications.^{1–3} The most common nerve damage-associated complications are recurrent laryngeal nerve (RLN) palsy, hypoglossal nerve

palsy, and palsy of the external branch of the laryngeal nerve or lingual nerve. Hansch et al. determined a 1.9% incidence of unilateral RLN palsy during laryngoscopy.³ The net incidence associated with isolated hypoglossus nerve palsy or lingual nerve palsy is unknown, although it is low.^{4–6} Cases of isolated hypoglossal nerve palsy or lingual nerve palsy associated with endotracheal intubation have been reported after the use of the laryngeal mask airway (LMA) in recent years.^{2,7–9} We discuss a case of combined unilateral nervus hypoglossus and nervus lingualis paresis developing after septorhinoplasty surgery under GA in the light of the literature.

* Corresponding author.

E-mail: hulyaulusoy.md@gmail.com (H. Ulusoy).

Case report

A 19-year-old female patient in the ASA I risk group was operated by an ENT surgeon due to nasoseptal deformity. The patient had been operated on 2 years previously for the same reason but had experienced no GA-associated problem. Preoperative examination revealed a 4-cm mouth opening, and the soft palate and uvula were visualized. Her Mallampati score was 2, and the thyromental distance and sternomental distance were normal. Atlanto-occipital joint extension was adequate. GA was performed using intravenous (iv) pentothal (5 mg/kg), fentanyl (1 µg/kg) and vecuronium (0.1 mg/kg). Mask ventilation was performed with difficulty using a bilateral triple maneuver in order to reduce air leakage due to face-mask incompatibility. A No. 4 airway was inserted to improve ventilation. Laryngoscopy was performed using a Macintosh blade (No. 3). Cricoid pressure was applied to improve visualization. An endotracheal tube (ETT) (7.5 mm, red rubber; Rusch™) was inserted into the trachea at the first attempt. Once the placement of the tube had been confirmed, the cuff of the ETT was inflated so as not to exceed 20 cmH₂O. The location of the ETT inside the mouth was altered to the left side of the tongue due to the position of the patient anesthesia device. It was later located by attachment to the edge of the left lower lip. GA was maintained with a sevoflurane and oxygen/N₂O mixture. The operation was continued with the head and neck in the central line, with the patient in a semi-supine position with slight extension to the anterior. A small throat pack was inserted alongside the tube and removed before extubation.

Surgery lasted 180 min, and the patient's vital findings were stable. The patient was extubated with no problem and monitored in the PACU until attaining a Modified Aldrete Score ≥ 9 . Sore throat and hoarseness appeared during observation on the ward on the 1st day postoperatively. Examination revealed a palpable mass, approximately 1 cm in diameter, in the angulus mandibulae in the left submandibular region. At indirect laryngoscopic examination, the uvula was edemic and hyperemic and vocal cord movements were free. The patient was told that the condition might be temporary, and anti-inflammatory therapy was initiated. Difficulty in swallowing and speaking and inability to use the tongue developed on the 2nd day, and neurological and ENT examinations were performed. No abnormality was determined at external oral examination, though there was pronounced edema in the tongue, particularly on the left, restricted tongue movement to the right and deviation to the left (Fig. 1). On the 3rd day postoperatively, pronounced loss of taste sensation was determined in the front two-thirds on the left of the tongue. Other cranial nerve examinations were normal. Apart from a 1-cm lymphadenopathy in the left submandibular region, no additional pathology was identified at MRI of the head and neck. Unilateral paralysis of the nervus hypoglossus and nervus lingualis was diagnosed. The patient was explained that this nerve damage might also involve permanent symptoms and the treatment protocol was set out. Intravenous prednol at a dosage of 1 mg/kg was used for the first 3 days, followed by peroral administration. Speech and swallowing therapy were initiated. The dosage was gradually reduced after the 10th day, and steroid was stopped on the 20th day. Vitamins E, B1 and B6 were continued for 1 month. However, when nerve damage was

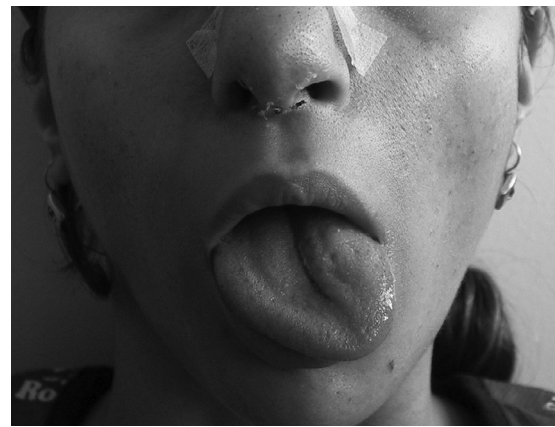


Figure 1 Deviation to the left in the tongue associated with unilateral paralysis of the hypoglossal nerve on the 3rd day postoperatively.

diagnosed the patient experienced severe anxiety and sleep impairment, and a consultation was held with the psychiatry department. The patient exhibited depressive affectivity and anxiety at evaluation and was diagnosed with depression, anxiety disorder and conversion disorder. The selective serotonin reuptake inhibitor (SSRI) escitalopram (CIPRALEX® Film Tablet, Lundbeck, Denmark) was started at a dosage of 10 mg po on the 4th day. There was a slight improvement in sore throat and swallowing difficulty on the 7th day of treatment. Pronounced atrophy was seen in the left lingual mucosa. Speech impairment, inability to use the tongue and loss of sense of taste began to decline at examinations in the 3rd week. There was a significant improvement in taste perception and the atrophic appearance in the tongue at the end of the 3rd month. The patient's anxiety, depression, sleeplessness and problems associated with isolation from society improved and SSRI therapy was stopped at the end of the 12th week. All symptoms resolved by the end of the 6th month.

Discussion

A wide range of upper airway problems may be observed post-GA, from minor sore throat and pharyngeal dryness to impaired speech, hoarseness and respiratory difficulty.¹ In the case described here, combined neuropraxia of the hypoglossal and lingual nerves developed following intubation GA for septorhinoplasty surgery.

Isolated hypoglossal nerve damage associated with laryngoscopy and tracheal intubation is usually unilateral and is seen as a rare postoperative complication with multifactorial causes.^{2,10} Other causes include use of the LMA, application of cricoid pressure and direct compression of the hypoglossal nerve beneath the angle of the mandible angle during mask ventilation.^{11,12} It is notable that in most case reports unilateral hypoglossal nerve injury develops on the left side.^{8,11,12} Hypoglossal paresis may sometimes not be isolated after endotracheal intubation, and may be comorbid with vocal cord paralysis (RLN palsy) (Tapia's syndrome).⁴ Most of these case reports have emerged after septo- and/or rhinoplasty under GA. Use of a throat pack during this operation and the position given to the head

and neck are nerve injury risks associated with the surgery. Large throat packs in particular can cause direct lingual and hypoglossal nerve injury in this operation.^{7,13-15}

Lingual nerve damage is more commonly seen during dental procedures. It is rarer in association with laryngoscopy and endotracheal intubation.¹⁶ Silva et al. reported lingual numbness and loss of taste sensation 24 h after conclusion of anesthesia in an obese patient who could not be intubated.⁷ However, lingual nerve damage may also appear in the 48th to 72nd hours as well as immediately after anesthesia and recovery.^{7,9}

Evers et al. described a case of combined hypoglossal and lingual nerve palsy with thickening of the soft tissue in the tongue and laryngeal structures in association with acromegaly and showed that prognathism facilitates laryngoscopy-associated lingual nerve injury.⁶ In that acromegalic patient, hyperextension of the head during transsphenoidal hypophysectomy or the tube being tightly attached in the neck may have caused combined injury of the hypoglossal and lingual nerves.⁶ Teichner and Jones reported that pressure to the cricoid caused hypoesthesia in the tongue in two separate cases.^{17,18} The cricoid pressure maneuver may cause stretching at the point where the lingual nerve passes through the hypoglossus muscle. On the other hand, Wang showed that improper placement of the oropharyngeal airway may lead to lingual nerve damage.¹⁹ James revealed that the lingual nerve can be injured by anterior displacement of the mandible.²⁰

There are very few cases of combined nerve damage in the literature, and the anatomical courses of these two nerves need to be examined in order to account for concomitant injury to them, as in our case.⁴⁻⁶ The hypoglossal nerve runs beneath the submandibular gland, the submandibular duct and the lingual nerve and intersects in the anterior of the hypoglossus muscle. This is where the lingual muscle is most superficial. Cricoid pressure, the triple maneuver or airway use can all become risk factors in this situation.

We evaluated the severity of the symptoms and the length of time to recovery from the nerve injury in our case as "neuropraxia" (class I; physiological block) according to the Seddon classification (1943) and "type 1" according to the Sunderland classification (1951). The form of nerve injury was in all probability compression type, similar to that in the literature.¹⁶

In our opinion, there may be five (other) possible causes, in addition to laryngoscopy, of the combined unilateral nervus hypoglossus and nervus lingualis paralysis in this case report. First, mask compression and the triple maneuver were performed to ensure adequate ventilation during anesthesia induction (constant bilateral anterior pressure at the mandibular angles). Second, the oropharyngeal airway was in the oral cavity during the triple maneuver. This maneuver may have increased the pressure effect of the airway on the tongue. Third, cricoid pressure was applied during laryngoscopy in order to improve visualization. Fourth, the ETT used was high pressure, low volume, non-flexible red-rubber, and the ETT was relocated from the right to the left non-flexible. Fifth, although the head and neck were not placed in an extreme anterior position, the ETT was tightly attached. Although these probably factors may appear harmless in day-to-day practice, their simultaneous occurrence may have facilitated nerve injuries.

There is no proven beneficial protocol for cranial nerve injuries in the literature, although the benefits of high-dose steroid therapy have been shown in Bell's palsy.²¹ Corticosteroids may reduce secondary injury by reducing tissue edema and inflammation.¹⁶ In addition to steroid therapy, combinations of anti-inflammatory drugs and vitamin B are also agreed to be beneficial. However, uncertainty over the outcomes of therapy and impaired speech and sense of taste, significant components of daily life, may also give rise to severe psychiatric problems. Individual social fear and anxiety require psychiatric monitoring and treatment. Psychiatric symptom may develop in parallel to neurological symptoms. Neuropraxia-type injuries generally resolve in 4-6 months with this therapy, as in our case.

Conclusion

Combined paralysis of the hypoglossal and lingual nerves following orotracheal intubation for GA is a rare condition in the literature. Importance must be attached to early postoperative visits and careful questioning of the patient, and to collaboration between the neurologist, otolaryngologist and, if required, the psychiatrist. Accurate and careful airway management and routine procedures during GA can reduce the risks during anesthesia and extubation. In order to reduce their anxiety, patients should be adequately informed about the resolution of generally temporary symptoms.

Conflicts of interest

The authors declare no conflicts of interest.

References

1. Zuccherelli L. Postoperative upper airway problems. *Southern Afr J Anesth Analg*. 2003;5:12-6.
2. Baumgarten V, Jalinski W, Böhm S, et al. Hypoglossal paralysis after septum correction with intubation anesthesia. *Anaesthesist*. 1997;46:34-7.
3. Friedrich T, Hänsch U, Eichfeld U, et al. Recurrent laryngeal nerve paralysis as intubation injury? *Chirurg*. 2000;71:539-44.
4. Agnoli A, Strauss P. Isolated paresis of hypoglossal nerve and combined paresis of hypoglossal nerve and lingual nerve following intubation and direct laryngoscopy. *HNO*. 1970;18:237-9.
5. Loughman E. Lingual nerve injury following tracheal intubation. *Anaesth Intensive Care*. 1983;11:171.
6. Evers KA, Eindhoven GB, Wierda JM. Transient nerve damage following intubation for trans-sphenoidal hypophysectomy. *Can J Anaesth*. 1999;46:1143-5.
7. Silva DA, Colingo KA, Miller R. Lingual nerve injury following laryngoscopy. *Anesthesiology*. 1992;76:650-1.
8. Nan-Kai Hung NK, Lee CH, Chan SM, et al. Transient unilateral hypoglossal nerve palsy after orotracheal intubation for general anesthesia. *Acta Anaesthesiol Taiwan*. 2009;47:48-50.
9. Inacio R, Bastardo I, Azevedo C. Lingual nerve injury: a complication associated with the classic laryngeal mask airway? *Internet J Anesthesiol*. 2010;23, <http://dx.doi.org/10.5580/19ba>.
10. Dziewas R, Ludemann P. Hypoglossal nerve palsy as complication of oral intubation, bronchoscopy and use of the laryngeal mask airway. *Eur Neurol*. 2002;47:239-43.
11. Venkatesh B, Walker D. Hypoglossal neuropraxia following endotracheal intubation. *Anaesth Intensive Care*. 1997;25:699-700.

12. Mullins RC, Drez Jr D, Cooper J. Hypoglossal nerve palsy after arthroscopy of the shoulder and open operation with the patient in the beach-chair position. A case report. *J Bone Joint Surg Am.* 1992;74:137–9.
13. Yavuzer R, Bařterzi Y, Özköse Z, et al. Tapia's syndrome following septorhinoplasty. *Aesth Plast Surg.* 2004;28:208–11.
14. Tesei F, Poveda LM, Strali W, Tosi L, Magnani G, Farneti G. Unilateral laryngeal and hypoglossal paralysis (Tapia's syndrome) following rhinoplasty in general anaesthesia: case report and review of the literature. *Acta Otorhinolaryngol Ital.* 2006;26:219–21.
15. Boęa I, Aktas S. Treatment, classification, and review of Tapia Syndrome. *J Craniofac Surg.* 2010;21:278–80.
16. Graff-Radford SB, Evans RW. Lingual nerve injury. *Headache.* 2003;43:975–83.
17. Teichner RL. Lingual nerve injury: a complication of orotracheal intubation. Case report. *Br J Anaesth.* 1971;43:413–4.
18. Jones BC. Lingual nerve injury: a complication of intubation. *Br J Anaesth.* 1971;43:730.
19. Wang KC, Chan WS, Tsai CT, et al. Lingual nerve injury following the use of an oropharyngeal airway under endotracheal general anesthesia. *Acta Anaesthesiol Taiwan.* 2006;44:119–22.
20. James FM. Hypesthesia of the tongue. *Anesthesiology.* 1975;42:359.
21. Lagalla G, Logullo F, Di Bella P, et al. Influence of early high-dose steroid treatment on Bell's palsy evolution. *Neurol Sci.* 2002;23:107–12.