



REVISTA BRASILEIRA DE ANESTESIOLOGIA

Official Publication of the Brazilian Society of Anesthesiology
www.sba.com.br



CLINICAL INFORMATION

Percutaneous endovascular removal of intracardiac migrated port A catheter in a child with acute lymphoblastic leukemia

Feraye Cakır^a, Sukran Geze^{b,*}, M. Halil Ozturk^a, Hasan Dınc^c

^a Department of Radiology, Medical Park Hospital, Ordu, Turkey

^b Department of Anesthesiology and Critical Care, Faculty of Medicine, Karadeniz Technical University, Trabzon, Turkey

^c Department of Radiology, Faculty of Medicine, Karadeniz Technical University, Trabzon, Turkey

Received 16 October 2012; accepted 21 November 2012

Available online 16 October 2013

KEYWORDS

Catheter;
Cardiac;
Migration;
Percutaneous

Abstract

A 2-year-old boy with acute lymphoblastic leukemia was presented with peripherally inserted central catheter dysfunction. Radiological examinations revealed a catheter remnant in the right atrium extending into pulmonary vein. The catheter remnant was successfully removed from the right atrium by percutaneous endovascular intervention without any complications.

© 2013 Sociedade Brasileira de Anestesiologia. Published by Elsevier Editora Ltda. All rights reserved.

PALAVRAS-CHAVE

Cateter;
Cardíaco;
Migração;
Percutâneo

Remoção endovascular percutânea de cateter totalmente implantável com migração intracardíaca em criança com leucemia linfoblástica aguda

Resumo

Menino com dois anos de idade com leucemia linfoblástica aguda foi apresentado com disfunção de cateter central perifericamente inserido. O exame radiológico revelou um fragmento do cateter no átrio direito que se estendia até a veia pulmonar. O fragmento foi removido com sucesso por intervenção endovascular percutânea, sem qualquer complicação.

© 2013 Sociedade Brasileira de Anestesiologia. Publicado por Elsevier Editora Ltda. Todos os direitos reservados.

Introduction

Central venous catheters are used frequently in pediatric patients. Especially port A catheters are inserted for the

purpose of injection of the chemotherapeutic agents in the treatment of malignancy or high caloric total parenteral nutrition in children. The port A catheter consists of an injection port with a self-sealing silicone septum and a radio-opaque silicone or polyurethane catheter. The port A catheter usually is placed in the interventional radiology units. Post insertion complications including leaks, accidental removal, migration of the tip, fracture, embolization, infection, occlusion of the catheter, venous perforation,

* Corresponding author.

E-mails: drgezesh@yahoo.com, gezesh@hotmail.com (S. Geze).

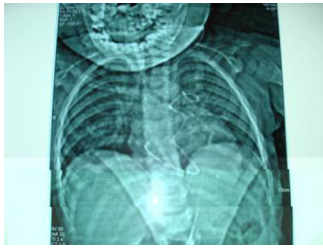


Figure 1 A broken port A catheter fragment in a 2-year-old male with acute lymphoblastic lymphoma was dislodged in the right ventricle reaching the main pulmonary vein.

atrial perforation, arrhythmias, and phlebitis previously are reported.¹⁻³ Catheter fragments centrally embolized in the heart and pulmonary artery has been also previously reported.^{1,4,5} If the migrated fragments are not removed, they may cause serious complications and death as well. Long term serious complications are changed between 21 and 33%⁶⁻⁸ and death rate is changed between 23.7 and 60%.⁶⁻⁹ Percutaneous removal of these migrated fragments decreased the need for major surgery.

We present successful percutaneous endovascular removal of port A catheter fragment migrated into the right ventricle in a 2-year-old boy with acute lymphoblastic leukemia (ALL).

Case report

A 8F port-A catheter (Polysite, France.) was inserted in a 2-year-old boy with ALL (acute lymphoblastic leukemia) for chemotherapy. Three months later a port revision was planned due to dysfunction. However, the family did not accept the intervention. The port was tried to be removed by the pediatric surgeons. The diaphragm of the port could be removed without the distal catheter. A chest X-ray (Fig. 1) and computed tomography revealed a distal catheter in the right atrium.

An emergency percutaneous removal of the catheter was planned. A vascular introducer was inserted into the right jugular vein with ultrasonic and fluoroscopic guidance under general anesthesia. The remnant of the port catheter was lying in the right atrium and reaching to the main pulmonary vein. The migrated port catheter was pulled back to the vena cava superior with manipulations of a 5F pigtail diagnostic catheter (Cordis, USA). Thereafter a snare catheter (Microvena, USA) was introduced. The catheter tip was successfully caught with the snare catheter and removed smoothly through the vascular sheath. At the end of the procedure, patency of the atrium and vessels was confirmed with an angiography.

Discussion

Central catheters have been used in the treatment of patients with cancer for more than twenty years for delivery of fluids, sclerosing agents and chemotherapeutics. Port catheters can be used for long time intravenous treatments. They are cosmetically accepted by patients and are more hygienic. The use of central catheters in oncology patients at the beginning of the treatment reduces the extrava-

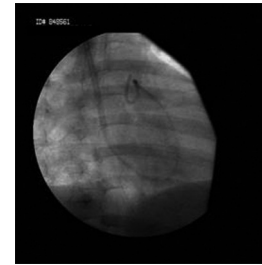


Figure 2 The fragment was repositioned into superior vena cava (SVC) with a 6F pigtail catheter. Thereafter its distal free end was captured by a snare in SVC and removed successfully.

sation risk of irritating chemotherapeutic agents, enables continuous peripheral access, and prevents patients' anxiety related with multiple venous puncture.

It has been reported that applications of the port catheters by interventional radiologists are safe. Complications after catheter insertion are: embolization, infection, occlusion of the catheters, venous perforation, atrial perforation, arrhythmias, flebitis, leakage, migration and breakage of the catheters.¹⁻³

There are several factors affecting the breakage of the central venous catheters. The breakage points of peripherally inserted central catheters are generally close to the insertion point, and the catheters break more easily when they are inserted in places of repeated stress, like elbow or iliac crease. The history of occlusion or flushing difficulty should be investigated for the catheter integrity, especially when the catheter dwelling time is long.⁶

Breakage and embolization of peripherally inserted central catheters is more often than expected especially in pediatric patients. Care givers to these patients should be trained about breakage and leakage of the catheters. Flushing of the catheter lines should be made with injectors smaller than 5 mL to prevent catheter breakage caused by excessive forces.⁶

In the past, surgery was the only choice in the treatment of broken and migrated catheters. Recently, percutaneous removal of migrated catheter parts is possible with much lower morbidity and mortality when compared with surgery. However in low birth weight babies percutaneous removal may cause serious complications such as vascular rupture or atrial perforation, but these procedures still have less morbidity and mortality when compared with open heart surgery.

The success rates of percutaneous removal of intravenous foreign bodies in the literature are 71–100%.¹⁰ The failure

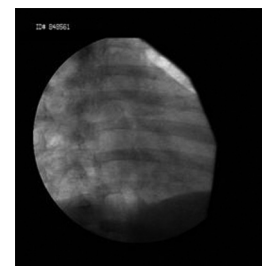


Figure 3 At the end of the procedure patency of the atrium and vessels was confirmed with an angiography.

of percutaneous removal is generally related to factors such as lack of a free end of the foreign body migration of the small catheter parts to peripheral arterial branches, immersion of the foreign body into the vascular wall, presence of the foreign body in a thrombosed vascular segment, and extravasation of the foreign body.

The problems of the absence of a free-end and migration of small fragments to the peripheral arteries could be overcome with the use of appropriate material and technique.

In our case the problems were distal intra-cardiac localization of the catheter and absence of a free-end because of the overlapping of the free-ends of the catheter. Thus, the catheter remnant could not be handled with the maneuvers of a snare catheter. The proximal end of the catheter was released with the aid of a pigtail diagnostic catheter and pulled out to the superior vena cava. Thereafter the catheter remnant was successfully and easily removed with the help of a snare catheter (Figs. 2 and 3).

Conflicts of interest

The authors declare no conflicts of interest.

References

1. Chen CC, Liang CD, Huang CF, et al. Percutaneous removal of a peripherally inserted central catheter remnant using cardiac catheterization. *Pediatr Int.* 2006;48:430–2.
2. Loughran SC, Borzatta M. Peripherally inserted central catheters: a report of 2506 catheter days. *J Parenter Enteral Nutr.* 1995;19:133–6.
3. Graham DR, Keldermans MM, Klemm LW, et al. Infectious complications among patients receiving home intravenous therapy with peripheral, central, or peripherally placed central venous catheters. *Am J Med.* 1991;91:95–100.
4. Linz DN, Bisset GS, Warner BW. Fracture and embolization of a peripherally inserted central venous catheter. *J Parenter Enteral Nutr.* 1994;18:79–80.
5. Thanigaraj S, Panneerselvam A, Yanos J. Retrieval of an IV catheter fragment from the pulmonary artery 11 years after embolization. *Chest.* 2000;117:1209–11.
6. Liu JC, Tseng HS, Chen CY, et al. Percutaneous retrieval of 20 centrally dislodged Port-A catheter fragments. *J Clin Imaging.* 2004;28:223–9.
7. Richardson JD, Grover FL, Trinkle JK. Intravascular catheter emboli: experience with twenty cases and collective review. *Am J Surg.* 1974;128:722–7.
8. Fisher RG, Ferreyro R. Evaluation of current techniques for non-surgical removal of intravascular iatrogenic foreign bodies. *Am J Roentgenol.* 1978;130:541–8.
9. Bernhardt LC, Wegner GP, Mendenhall JT. Intravenous catheter embolization to pulmonary artery. *Chest.* 1970;57:329–32.
10. Dondelinger RF, Lepontre B, Kurdziel JC. Percutaneous vascular foreign body retrieval experience of an 11-year period. *Eur J Radiol.* 1991;12:4–10.