



REVISTA BRASILEIRA DE ANESTESIOLOGIA

Publicação Oficial da Sociedade Brasileira de Anestesiologia
www.sba.com.br



CLINICAL INFORMATION

Anesthesia for pulmonary trunk aneurysmorrhaphy



Benedito Barbosa João^{a,b,c,*}, Ronaldo Machado Bueno^{b,d},
Guilherme D'Addazio Marques^b, Felipe Batista Soares^e

^a Universidade Federal de São Paulo (Unifesp), São Paulo, SP, Brazil

^b Hospital Beneficência Portuguesa, São Paulo, SP, Brazil

^c Hospital Euryclides de Jesus Zerbini, São Paulo, SP, Brazil

^d Instituto do Coração do Hospital das Clínicas – Incor (FMUSP), São Paulo, SP, Brazil

^e Hospital Municipal de São José dos Campos, São José dos Campos, SP, Brazil

Received 27 January 2013; accepted 22 March 2013

Available online 18 March 2015

KEYWORDS

General anesthesia;
Anesthetic:
inhalational;
Surgery:
aneurysmorrhaphy

Abstract

Background and objectives: The aneurysm in the pulmonary trunk is a rare disease. Because of its location, a rupture can lead to right ventricular failure and sudden death. Aneurysmorrhaphy is the most widely used surgical treatment in these cases. The aim of this study is to report a successful balanced general anesthesia for aneurysmorrhaphy of pulmonary trunk.

Case report: Male patient, 28 years, asymptomatic, diagnosed with an aneurysm in the pulmonary trunk. According to the location of the aneurysm and the consequent failure of the pulmonary valve, an aneurysmorrhaphy was indicated, with implantation of vascular-valvular prosthesis (valved tube). We opted for a balanced general anesthesia, seeking to prevent an increase in systemic and pulmonary vascular resistances, thus avoiding to cause stress on the wall of the aneurysmal vessel.

Conclusions: A balanced general anesthesia, in combination with adequate ventilation to prevent elevation in pulmonary vascular pressure, was appropriate for surgical repair of an aneurysm in the pulmonary trunk.

© 2014 Sociedade Brasileira de Anestesiologia. Published by Elsevier Editora Ltda. This is an open access article under the CC BY-NC-ND license (<http://creativecommons.org/licenses/by-nc-nd/4.0/>).

* Corresponding author.

E-mail: beneditobj@uol.com.br (B.B. João).

PALAVRAS-CHAVE

Anestesia geral;
Anestésico:
inalatório;
Cirurgia:
aneurismorrafia

Anestesia para aneurismorrafia de tronco de artéria pulmonar**Resumo**

Justificativa e objetivos: O aneurisma de tronco de artéria pulmonar é uma doença rara. Por sua localização, uma ruptura pode conduzir à falência do ventrículo direito e à morte súbita. A aneurismorrafia é o tratamento cirúrgico mais usado nesses casos. O objetivo foi relatar uma anestesia geral balanceada para aneurismorrafia de tronco de artéria pulmonar feita com sucesso.

Relato do caso: Paciente do sexo masculino, 28 anos, assintomático, diagnosticado com aneurisma de tronco de artéria pulmonar. De acordo com a localização do aneurisma e a consequente insuficiência da válvula pulmonar, foi indicada a aneurismorrafia com implante de prótese vascular e valvular (tubo valvado). Optou-se pela anestesia geral balanceada, para impedir um aumento nas resistências vasculares sistêmicas e pulmonar e evitar-se, dessa maneira, um estresse sobre a parede do vaso aneurismático.

Conclusões: A anestesia geral balanceada, em associação com uma ventilação adequada para evitar elevação na pressão vascular pulmonar, foi apropriada para correção cirúrgica de um aneurisma em tronco pulmonar.

© 2014 Sociedade Brasileira de Anestesiologia. Publicado por Elsevier Editora Ltda. Este é um artigo Open Access sob uma licença CC BY-NC-ND (<http://creativecommons.org/licenses/by-nc-nd/4.0/>).

Introduction

Aneurysm is the focal dilatation of a vessel. Although it may occur in vessels of the venous system,¹ it is more frequent in arteries and affects its three tunics (intima, media, and adventitia). It is classified as fusiform, if symmetric and dilatation involving the entire circumference, or saccular, if asymmetric and only a part of the circumference is dilated.

Unlike the aorta, which is the most affected by that disease, pulmonary artery aneurysm (PAA) is a rare occurrence.² However, even in a low pressure circuit as the lung, it is subject to the same hemodynamic forces that promote the growth of the aorta or other arteries when affected by an aneurysm.²

The etiological causes of disease may be idiopathic, congenital heart defects (e.g., *patent ductus arteriosus*), vasculitis (autoimmune, postinfection or genetic factors), and connective tissue diseases such as Marfan syndrome, among others.^{3,4}

Clinically, it may be manifested by dyspnea, cough, hemoptysis, and chest pain.³ However, most patients with PAA are asymptomatic.^{2,5} The diagnosis is made at random by routine screening.

The presence of pain is a symptom that indicates impending rupture. In this case, surgical treatment is recommended to prevent sudden death (SD) caused by the aneurysm rupture and right ventricle (RV) failure.⁶

Even when there is no pain, but the pulmonary trunk is involved, the risk of SD is also high for the same reasons cited above, and many authors suggest surgery.⁷

We report a rare case of anesthesia for surgical treatment of pulmonary trunk aneurysm (aneurysmorrhaphy) in an asymptomatic patient with Marfan syndrome.

The purpose of anesthesia was to keep under control both systemic blood pressure (SBP) and pulmonary arterial pressure (PAP).

Therefore, we sought to avoid rupture of the aneurysm, its disastrous consequences in vascular site, and possible damage after surgical correction.

Case report

Male patient, 28 years old, white, 67 kg, 1.90 m, diagnosed with a pulmonary trunk aneurysm, without other comorbidities.

The patient had no signs or symptoms of the disease. The diagnosis was made during a periodic medical examination at the company where he worked.

In the evaluation of the first tests, an increased heart size by the growth of the right ventricle and pulmonary artery trunk was noticed (Fig. 1). The electrocardiogram showed a deviation of the QRS axis to the right and a right bundle branch block.

A Doppler echocardiography was requested, which revealed moderate dilatation and hypertrophy of the right

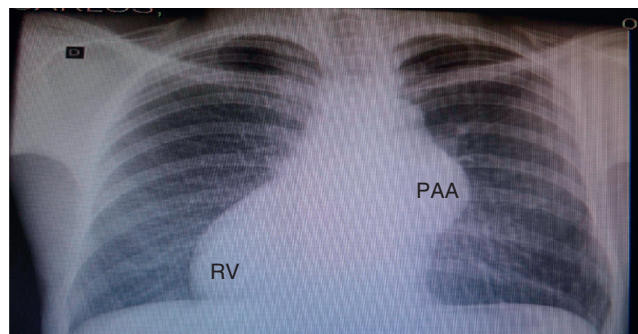


Figure 1 Chest X-ray: PAA aneurysm, increased RV, and deviation of the cardiac area to the right. PAA, pulmonary artery trunk; RV, right ventricle.

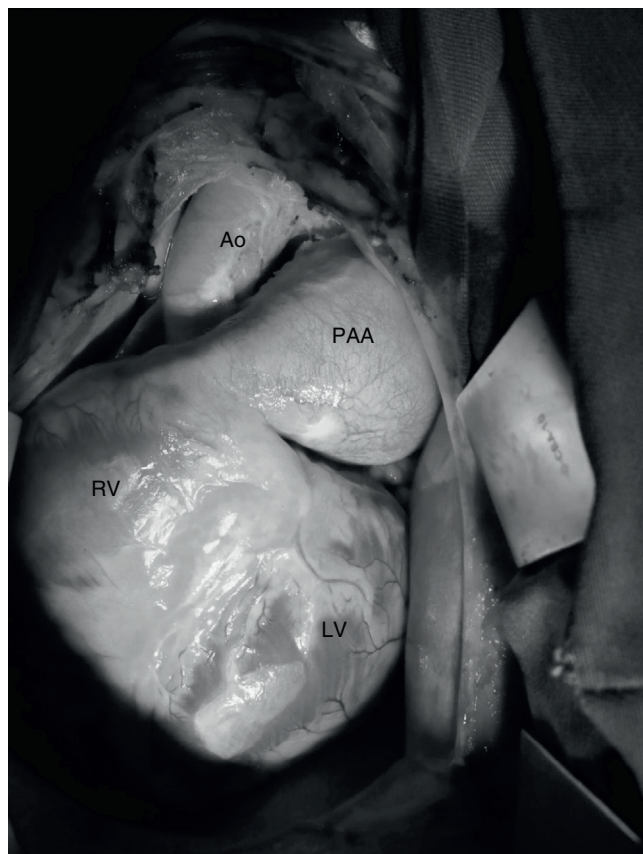

Figure 2 PAA aneurysm and increased RV; PAA, pulmonary artery trunk; RV, right ventricle; Ao, aorta; LV, left ventricle.

ventricle, significant dilation of the pulmonary artery trunk and its branches, and dysplasia with severe pulmonary valve insufficiency. Mean pulmonary artery pressure was estimated at 30 mmHg (normal reference value: 10–18 mmHg).

After these tests, the patient was sent to the hospital *Beneficência Portuguesa* (São Paulo, Brasil), where a pulmonary artery computed angiography was performed. The following relevant aspects were observed: aneurysmal dilatation of the pulmonary artery trunk measuring 5.8 cm in diameter; pulmonary valve annulus measuring 3.6 cm × 3.5 cm diameter; medianized heart showing signs of right ventricle dilatation and its outflow.

With the diagnosis of pulmonary artery aneurysm (Fig. 2) and pulmonary valve annulus dilation (with impaired valve), aneurysmorrhaphy was indicated, with synthetic Dacron tube and metal valve implantation in pulmonary position (valved tube).

On the operation day, the patient was taken to the operating room and monitored with electrocardioscope, pulse oximeter, and noninvasive blood pressure. A large venous access was placed in the right upper limb and midazolam (3 mg) was administered to provide anxiolysis/sedation. At that time, with normal values of heart rate and blood pressure, dexmedetomidine infusion was started at a dose of 0.5 $\mu\text{g kg}^{-1} \text{ h}^{-1}$ for 15 min, sufficient time to left radial artery catheterization in order to invasively measure the pressure.

Induction of anesthesia started with preoxygenation (100% O_2), reduction of dexmedetomidine to 0.4 $\mu\text{g kg}^{-1} \text{ h}^{-1}$,

fentanyl 10 $\mu\text{g kg}^{-1}$ etomidate 20 mg, rocuronium 0.6 mg kg^{-1} , and intravenous lidocaine 2 mg kg^{-1} . After the required time for drug action, tracheal intubation was performed without complications, such as hypertension or tachycardia. Monitoring was completed with capnography and central venous pressure.

The mechanical ventilation was adjusted to FiO_2 of 60%, with a frequency of 12 breaths per minute, tidal volume of 7 mL kg^{-1} , and positive end-expiratory pressure (PEEP) of 3 cmH_2O , in order to maintain EtCO_2 between 30–32 mmHg.

Maintenance of anesthesia was achieved with 1% isoflurane, dexmedetomidine (0.4 $\mu\text{g kg}^{-1} \text{ h}^{-1}$), and additional doses of fentanyl to complete 20 $\mu\text{g kg}^{-1}$. Midazolam and rocuronium were administered again during cardiopulmonary bypass (CPB), with another supplemental dose of muscle relaxant at the end of CPB.

Epsilon-aminocaproic acid, an antifibrinolytic, was infused at a dose of 100 mg kg^{-1} in the first hour of surgery, followed by 10 $\text{mg kg}^{-1} \text{ h}^{-1}$ in order to inhibit fibrinolysis and reduce surgical bleeding.

With ventilatory adjustments described above, maintenance of blood gas values within normal limits, and the used drugs, we sought to prevent any event that promotes increased systemic or pulmonary arterial blood pressure⁸ that could increase the risk of aneurysm rupture until CPB.

CPB was performed with moderate hypothermia, and aneurysmorrhaphy with replacement by vascular prosthesis and metallic prosthetic valve was uneventful.

At the end of CPB, the possible RV dysfunction as a result of the ischemia period—reperfusion on a dilated/hypertrophic ventricle—was prevented by the choice of positive inotropic and vasodilator milrinone.

The initial bolus of this inotropic⁹ was suppressed and an infusion of 0.5 $\mu\text{g kg}^{-1} \text{ min}^{-1}$ of the drug was started still in CPB. This dose was continued until after the end of CPB and protamine administration. Maintenance was then reduced to 0.3 $\mu\text{g kg}^{-1} \text{ min}^{-1}$ for another hour and, because contractile performance was very satisfactory, the drug infusion was stopped. Discontinuation of milrinone was made to avoid a possible hypotension as a result of this drug synergism with dexmedetomidine.

The patient remained stable until the end of surgery and was taken to the ICU intubated and with continuous infusion of dexmedetomidine.

Discussion

The tendency of any aneurysm is to continue gradually dilating. Dilation leads to a stress on the vessel wall, a determining factor for its rupture.¹⁰ Pulmonary artery aneurysm is a rare disease^{2,7} and there is no guideline for treatment.^{11–13}

Therapy may vary from conservative^{7,12} to surgical^{2,3} according to the aneurysm location or in the presence of pain as a symptom, for example.³ The invasive procedures range from lobectomy and embolization in more distal arteries to pneumonectomy when the main pulmonary artery is involved.^{2,3}

When the aneurysm affects this artery trunk, as in the case reported here, the treatment is surgical. At this location, there is a risk that the vessel disruption leads to RV

failure and sudden death. Aneurysmorrhaphy is the most commonly used surgery in such cases.²

Pulmonary artery trunk aneurysmorrhaphy is performed under sternotomy and with cardiopulmonary bypass (CPB). However, it does not differ from many of the cardiac surgeries routinely performed.

The specific surgical time of these types of cardiovascular procedures (sternotomy, pericardiotomy, aorta management and cannulation, among others) is a potent stimulus to the sympathetic nervous system and may raise blood pressure. As a result, according to Laplace's law, an increased blood pressure (or increased vessel diameter) exacerbates the tension on the aneurysm wall making it unstable and prone to rupture.^{2,14,15}

Regarding pulmonary artery aneurysm, besides the concern with hypertension, an additional challenge arises: preventing an increase in pulmonary vascular resistance (PVR). An increased resistance in this site would be transmitted to the pulmonary trunk, with consequent additional stress on aneurysm and increased RV afterload.

In the case reported here, we avoid the factors that could contribute to increased PVR, such as hypoxia, decreased pH (hypercapnia/respiratory and metabolic acidosis),⁸ adrenergic and nociceptive stimuli.

Tidal volume (TV) and PEEP were reduced (TV = 7 mL kg⁻¹ and PEEP = 3 cm H₂O), because these factors when excessive during mechanical ventilation may cause pulmonary hyperdistension and, consequently, increase in pulmonary vascular resistance.¹⁶ Compensation with FiO₂ (60%) and respiratory rate (12 bpm) were sufficient for effective oxygenation control and CO₂ elimination.

Regarding the anesthetic technique: "almost any combination of anesthetics and vasoactive drugs has favorable studies and enthusiastic advocates who promote its use".¹⁷ There is no consensus among anesthesiologists about the most appropriate technique for pulmonary trunk aneurysmorrhaphy. Here we opted for balanced general anesthesia, as this modality has been routine in our service for cardiovascular surgery and results in good hemodynamic control.

Isoflurane, the inhaled agent chosen, has two desirable characteristics, among others, for the case reported here: first, it attenuates, by anesthetic preconditioning, the ischemia-reperfusion injury due to CPB;¹⁸ and second, it reduces pulmonary vascular resistance¹⁹ (although with less intensity in patients without pulmonary hypertension).²⁰

We also used dexmedetomidine, a potent α_2 -adrenoceptor agonist (α_2 -receptors consist of three subtypes: α_{2a} , α_{2b} e α_{2c}) with sympatholytic, sedative, amnesic and analgesic properties.²¹ Its selectivity regarding receptors α_1 and α_2 compared to clonidine, a congener, is eight times higher.

In 2006, But et al.,²² evaluating the effects of dexmedetomidine in patients with pulmonary hypertension (PH) undergoing cardiac surgery, concluded that dexmedetomidine, in addition to reducing the need for fentanyl, attenuated the increase in systemic vascular resistance index and pulmonary vascular resistance. It reduced the mean arterial pressure, mean pulmonary artery pressure, and pulmonary wedge capillary pressure compared to placebo group values.

In our case, the pressure was not measured in the more distal pulmonary capillaries as in the patients studied by the authors cited above. The mean pulmonary artery pressure (increased) could only be studied in the aneurysmal area by Doppler echocardiographic examination.

However, even without being able to tell if the pressure in the arterial bed distal to the aneurysm was increased, the administration of a drug capable of reducing the adrenergic response²³ and possibly pulmonary vasculature blood pressure²² allowed the inclusion of this agent in the anesthesia.

The bolus dose of dexmedetomidine (1 $\mu\text{g kg}^{-1}$) is purposely excluded. It is assumed that due to the effect on α_2 receptors on vascular smooth muscle, the bolus loading dose results in an increase in blood pressure²¹, which would be undesirable in patients with aneurysms. Much of the adverse effects of this drug occur during or shortly after the loading dose (bolus),²¹ so we opted for an infusion of 0.5 $\mu\text{g kg}^{-1} \text{h}^{-1}$ for 15 min and then reduce it to 0.4 $\mu\text{g kg}^{-1} \text{h}^{-1}$.

Continuous infusion of dexmedetomidine was maintained until the first hours of the patient arrival in the intensive care unit (ICU). Thereby, we seek to extubate the patient under the agent safe sedation and avoid respiratory depression²¹ and increased blood pressure.

The team was also concerned about the possibility of RV dysfunction after CPB. The right ventricle was hypertrophic/dilated, therefore, more susceptible to inadequate protection by cardioplegic solution, despite all care about the volume and injection time of cardioplegia. It was known beforehand that the time of aortic clamping during cardiopulmonary bypass (heart ischemia) would be from moderate to prolonged, due to the size of the surgery, and this could affect the myocardium.

To avoid a poor performance of the RV at the end of CPB, dilate the pulmonary vasculature, and reduce pressure on the surgical sutures (prosthesis and aneurysmorrhaphy), we opted for milrinone, a positive inotropic vasodilator and inhibitor of phosphodiesterase III (PDE III).

Phosphodiesterase III is an enzyme found in myocytes, blood vessels,²⁴ sarcoplasmic reticulum, and platelets.²⁵ Milrinone inhibits PDE III and reduces the hydrolysis of cyclic AMP (with less effect on cyclic GMP).

In myocardium, this action results in increased intracellular ionized calcium and heart contractile force mediated by the cyclic AMP.

In the smooth muscle of blood vessels, it causes a decrease in the concentration of intracellular calcium, resulting in intense vasodilation.²⁶ The vasodilator action of milrinone on pulmonary vasculature independent of β -receptors and may even exceed the action of β -agents, including isoproterenol, the most potent of all.²⁷

For anesthesia in a rare case, such as pulmonary artery trunk aneurysm, our choice was for balanced general anesthesia with the use of agents known to allow good control of systemic and pulmonary vascular resistance. The end result, even in the face of an uncommon disease, was satisfactory.

The patient was extubated in the ICU 2 h after the surgery. He was, therefore, included in the desirable regime of fast-track^{28,29} (extubation within 6–8 h after surgery). ICU discharge occurred on the second postoperative day and hospital discharged a week after the procedure, with the patient without any complication or sequela.

Conflicts of interest

The authors declare no conflicts of interest.

References

1. Ekim H, Gelen T, Karpuzoglu G. Multiple aneurysms of the cephalic vein. A case report. *Angiology*. 1995;46:265–7.
2. Bartter T, Irwin RS, Nash G. Aneurysm of pulmonary arteries. *Chest*. 1988;94:1065–75.
3. Samano MN, Ladeira RT, Meirelles LP, et al. Aneurisma de artéria pulmonar como manifestação da doença de Behçet. *J Pneumol*. 2002;28:150–4.
4. Araújo I, Escribano P, Lopez-Gude MJ, et al. Giant pulmonary artery aneurysm in a patient with vasoreactive pulmonary hypertension a case report. *BMC Cardiovasc Disord*. 2011;11:64.
5. Sakuma M, Demachi J, Suzuki J, et al. Proximal pulmonary artery aneurysms in patients with pulmonary artery hypertension: complicated cases. *Intern Med*. 2007;46:1789–93.
6. Shiraishi M, Yamaguchi A, Morita H, et al. Successful surgical repair of pulmonary artery aneurysm and regurgitation. *Ann Thorac Cardiovasc Surg*. 2012;18:491–3.
7. Kuwaki K, Morishita K, Sato H, et al. Surgical repair of the pulmonary trunk aneurysm. *Eur J Cardiothorac Surg*. 2000;18:535–9.
8. Rudolph AM, Yuan S. Response of the pulmonary vasculature to hypoxia and H⁺ ion concentration changes. *J Clin Invest*. 1966;45:399–411.
9. Baruch L, Patacsil P, Hameed A, et al. Pharmacodynamic effects of milrinone with and without a bolus loading infusion. *Am Heart J*. 2001;141:266–73.
10. Butto F, Lucas RV, Edwards JE Jr. Pulmonary arterial aneurysm. A pathologic study of five cases. *Chest*. 1987;91:237–41.
11. Imazio M, Cecchi E, Giammaria M, et al. Main pulmonary artery aneurysm: a case report and review of the literature. *Ital Heart J*. 2004;5:232–7.
12. Vural AH, Türk T, Ata Y, et al. Idiopathic asymptomatic main pulmonary artery aneurysm: surgery or conservative management? A case report. *Heart Surg Forum*. 2007;10:273–5.
13. Casselman F, Meyns B, Herygers P, et al. Pulmonary artery aneurysm: is surgery always indicated? *Acta Cardiol*. 1997;52:431–6.
14. Zamorano MMB. Dissecção e rotura da artéria pulmonar associada à persistência do canal arterial: relato de um caso. *Rev Bras Cir Cardiovasc*. 1987;2:139–44.
15. Oliveira MAB, Alves FT, Silva MVP, et al. Conceitos de física básica que todo cirurgião cardiovascular deve saber. Parte I – Mecânica dos fluidos. *Rev Bras Cir Cardiovasc*. 2010;25:1–10.
16. Auler Junior JOC. Monitoração hemodinâmica invasiva em pacientes com Sara. Mensuração da água extravascular pulmonar. *J Pneumol*. 1990;16:97–104.
17. Barash PG, Cullen BF, Stoelting RK. Anestesia clínica. 2ª edição brasileira Barueri: Manole; 2004. p. 883–928.
18. Tardelli MA. Agentes inalatórios e proteção de órgãos. In: Cavalcanti IL, Vane LA, editors. Anestesia inalatória. Rio de Janeiro: Sociedade Brasileira de Anestesiologia; 2007. p. 133–56.
19. Grogan K, Nyhan D, Berkowitz DE. Pharmacology of anesthetic drugs. In: Kaplan JA, et al., editors. *Kaplan's cardiac anesthesia*. 5th ed. Philadelphia: Elsevier Saunders; 2006. p. 165–212.
20. Ebert T, Schmid PG III. Anestesia inalatória. In: Barash PG, Cullen BF, Stoelting RK, editors. *Anestesia clínica*. 2ª edição brasileira Barueri: Manole; 2004. p. 377–417.
21. Afonso J, Reis F. Dexmedetomidine: current role in anesthesia and intensive care. *Rev Bras Anesthesiol*. 2012;62:118–33.
22. But AK, Ozgul U, Erdil F, et al. The effects of preoperative dexmedetomidine infusion on hemodynamics in patients with pulmonary hypertension undergoing mitral valve replacement surgery. *Acta Anaesthesiol Scand*. 2006;50:1207–12.
23. Arcangeli A, D'Alò C, Gaspari R. Dexmedetomidine use in general anaesthesia. *Curr Drug Targets*. 2009;10:687–95.
24. Elvebak RL, Eisenach JH, Joyner MJ, et al. The function of vascular smooth muscle phosphodiesterase III is preserved in healthy human aging. *Clin Transl Sci*. 2010;3:239–42.
25. Kikura M, Lee MK, Safon RA, et al. The effects of milrinone on platelets in patients undergoing cardiac surgery. *Anesth Analg*. 1995;81:44–8.
26. Levy JH, Bailey JM, Deeb GM. Intravenous milrinone in cardiac surgery. *Ann Thorac Surg*. 2002;73:325–30.
27. Braunwald E, Zipes DP, Libby P. *Tratado de medicina cardiovascular*, vol. 1, 6ª ed. São Paulo: Editora Roca; 2003. p. 588–90.
28. Lopes CR, Brandão CM, Nozawa E, et al. Benefits of non-invasive ventilation after extubation in postoperative period of heart surgery. *Rev Bras Cir Cardiovasc*. 2008;23:344–50.
29. Sato M, Suenaga E, Koga S, et al. Early tracheal extubation after on-pump coronary artery bypass grafting. *Ann Thorac Cardiovasc Surg*. 2009;15:239–42.