



REVISTA BRASILEIRA DE ANESTESIOLOGIA

Official Publication of the Brazilian Society of Anesthesiology
www.sba.com.br



SCIENTIFIC ARTICLE

Bedside prediction of right subclavian venous catheter insertion length

Yoon Ji Choi^a, Kyung-Don Hahm^{b,*}, Koo Kwon^b, Eun-Ho Lee^b, Young Jin Ro^b, Hong Seuk Yang^b

^a Department of Anesthesiology and Pain Medicine, Seoul Paik Hospital, College of Medicine, Inje University, Seoul, Republic of Korea

^b Department of Anesthesiology and Pain Medicine, Asan Medical Center, University of Ulsan College of Medicine, Seoul, Republic of Korea

Received 10 July 2013; accepted 8 October 2013

Available online 13 August 2014

KEYWORDS

Central venous catheter;
Clavicular notch;
Subclavian vein

Abstract

Background and objective: The present study aimed to evaluate whether right subclavian vein (SCV) catheter insertion depth can be predicted reliably by the distances from the SCV insertion site to the ipsilateral clavicular notch directly (denoted as I-IC), via the top of the SCV arch, or via the clavicle (denoted as I-T-IC and I-C-IC, respectively).

Method: In total, 70 SCV catheterizations were studied. The I-IC, I-T-IC, and I-C-IC distances in each case were measured after ultrasound-guided SCV catheter insertion. The actual length of the catheter between the insertion site and the ipsilateral clavicular notch, denoted as L, was calculated by using chest X-ray.

Results: L differed from the I-T-IC, I-C-IC, and I-IC distances by 0.14 ± 0.53 , 2.19 ± 1.17 , and -0.45 ± 0.68 cm, respectively. The mean I-T-IC distance was the most similar to the mean L (intraclass correlation coefficient = 0.89). The mean I-IC was significantly shorter than L, while the mean I-C-IC was significantly longer. Linear regression analysis provided the following formula: Predicted SCV catheter insertion length (cm) = $-0.037 + 0.036 \times \text{Height (cm)} + 0.903 \times \text{I-T-IC (cm)}$ (adjusted $r^2 = 0.64$).

Conclusion: The I-T-IC distance may be a reliable bedside predictor of the optimal insertion length for a right SCV cannulation.

© 2013 Sociedade Brasileira de Anestesiologia. Published by Elsevier Editora Ltda. All rights reserved.

* Corresponding author.

E-mail: thisisyjro@naver.com (K.-D. Hahm).

PALAVRAS-CHAVE

Cateter venoso central;
Entalhe clavicular;
Veia subclávia

Previsão do comprimento de inserção de cateter em veia subclávia direita à beira do leito**Resumo**

Justificativa e objetivo: O presente estudo teve como objetivo avaliar se a profundidade de inserção de cateter em veia subclávia (VSC) direita pode ser prevista de forma confiável pelas distâncias do local de inserção na VSC até a incisura clavicular ipsilateral (I-IC), passando diretamente pela parte superior do arco da VSC ou da clavícula (denominadas I-T-IC e I-C-IC, respectivamente).

Método: No total, 70 cateterismos de VSC foram estudados. As distâncias I-IC, I-T-IC e I-C-IC de cada caso foram mensuradas após a inserção do cateter guiada por ultrassom. O comprimento do cateter entre o local de inserção e a incisura clavicular ipsilateral (L) foi calculado por meio de radiografia.

Resultados: As diferenças em centímetros de L em relação às distâncias I-T-IC, I-C-IC e I-IC foram de $0,14 \pm 0,53$; $2,19 \pm 1,17$ e $0,45 \pm 0,68$ respectivamente. A média de I-IC foi significativamente menor que L, enquanto a média de I-C-IC foi significativamente maior. A análise de regressão linear forneceu a seguinte fórmula: Comprimento previsto da inserção de cateter em VSC (cm) = $-0,037 + 0,036 \times \text{Altura (cm)} + 0,903 \times \text{I-T-IC (cm)}$ (r^2 ajustado = 0,64).

Conclusão: A distância I-T-IC pode ser um preditivo confiável do comprimento de inserção ideal para canulação em VSC direita.

© 2013 Sociedade Brasileira de Anestesiologia. Publicado por Elsevier Editora Ltda. Todos os direitos reservados.

Introduction

Several landmarks,^{1,2} simple formulas,³ and electrocardiography⁴ have been used for the optimal insertion depth of the central venous catheter. However, for subclavian venous cannulations, such confirmatory techniques are of limited use.

A recent study⁵ suggested that adding (i) the distance between the insertion point of needle and the ipsilateral clavicular notch to (ii) the vertical distance between the carina and the ipsilateral clavicular notch generates a reliable tip position near the carina level that guides suitable and safe positioning of the central venous catheter tip above the pericardial reflection.¹ However, this method has some limitations. This method requires a chest radiograph that is needed to evaluate the vertical distance between the carina and the ipsilateral clavicular notch. And, the subclavian vein follows a curved path.⁶ Thus, this method may be shorter than the optimal insertion depth.

The aim of the present study was to evaluate whether several distances from the insertion point of needle to the ipsilateral clavicular notch, running directly (denoted as I-IC), via the subclavian vein top, or via the clavicle (denoted as I-T-IC and I-C-IC, respectively), are reliable bedside predictors of the optimal insertion length for ultrasound-guided right subclavian venous cannulation.

Method

Written informed consent was obtained from all patients after approval of the trial by the Institutional Review Board (2012-0104) and Clinical Research Information Service (KCT0000612). All patients required subclavian venous cannulation over the course of a 6 month period. The patients

who did not agree to participate in the study were excluded from this study, as were patients who had some spine or vessel deformities or in whom the positioning of the central venous catheter was inadequate.

Patient ages, gender, heights, and weights were recorded. On arrival in the operating room, the patients were monitored. After the induction of anesthesia, skin preparation and sterile draping were performed. Subclavian venous catheterization was performed by using a four-lumen central venous catheter (Arrow International Inc., Reading, PA, USA) and the infra-clavicular approach with a sonography-guided longitudinal view. The probe (SonoSite S-Series, Bothell, WA, USA) was placed parallel to the long axis of the subclavian vein and the needle was inserted adjacent to the short edge of the probe so that it remained visible as it traveled through the overlying tissues into the subclavian vein.^{7,8} Subsequently, the catheter was inserted by using a guide-wire. To determine the correct depth of catheter insertion, the patient's head and neck were placed in the neutral position after insertion of the catheter and an intra-operative full-inspiration chest radiograph was taken to establish the fact that the central venous catheter tip was at the level of the carina.² To optimize the position of the catheter tip, the catheter was moved back and forth. Fig. 1 depicts the key landmarks and the each distance was measured. The needle insertion point is denoted as I in Fig. 1, while the ipsilateral clavicular notch is denoted as IC. The length of the catheter between the needle insertion point and the ipsilateral clavicular notch is denoted as L and was calculated by subtracting the measured length of the catheter between the ipsilateral clavicular notch and the catheter tip (this length is denoted as A), which was measured by using chest radiography, from the actual total length of catheter between the needle insertion point and the catheter tip. The I-IC, I-T-IC and I-C-IC distances were

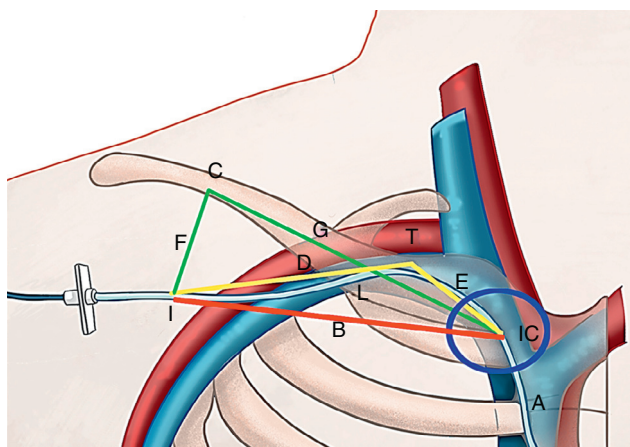


Figure 1 The I-T-IC, I-C-IC, and I-IC distances were measured after ultrasound-guided insertion of the right subclavian venous cannulation catheter. The blue circle indicates the ipsilateral clavicular notch (IC). The actual total catheter insertion length (L + A) was calculated by adding (i) the distance between the needle insertion point and the ipsilateral clavicular notch (this distance is designated as L) to (ii) the distance between the ipsilateral clavicular notch and the catheter tip (this distance is designated as A). The I-T-IC distance is the distance from the needle insertion point to the ipsilateral clavicular notch via the top of the subclavian vein (i.e., distance D + distance E) that is indicated by the yellow line. The I-C-IC distance is the distance from the needle insertion point to the ipsilateral clavicular notch via the clavicle (i.e., distance F + distance G) that is indicated by the green line. The I-IC distance is indicated by B and the red line, and is the direct distance from the needle insertion point to the ipsilateral clavicular notch.

measured on the surface of skin after inserting the subclavian vein cannulation catheter, and I-T-IC was guided by ultrasound. The I-IC distance is the direct line between the insertion point of needle and the ipsilateral clavicular notch; it is indicated in Fig. 1 by the red line and denoted as B. Point T, which was defined as the highest point of the subclavian vein arch, was determined by using ultrasound. The I-T-IC distance (denoted by the yellow line in Fig. 1) was determined by adding (i) the distance between the insertion point of needle and point T (the distance denoted by D) to (ii) the distance between point T and the ipsilateral clavicular notch (the distance denoted by E). The I-C-IC distance (denoted by the green line in Fig. 1) was determined by adding (i) the shortest distance between the clavicle (point C) and the insertion point of needle (the distance denoted by F) to (ii) the distance between the clavicle (point C) and the ipsilateral clavicular notch (the distance denoted by G).

Regarding sample size, it was determined that 75 measurements were needed for a significance level of 0.05, a power of 90%, and an exclusion rate of 15%. These determinations were based on the results of a previous study⁵ that reported a distance of 1 cm from the carina as being a safe central venous catheter tip level (the SD was 1.2 cm). All variables are expressed as mean ± standard deviation, or number of samples. A paired t-test with 95% confidence intervals was used to evaluate the differences between L and the I-T-IC, I-C-IC, or I-IC distances. The agreement

Table 1 Demographic characteristics of the patients.

Patient characteristics (n = 70)	
Age (years)	58.36 ± 15.11
Gender (M/F)	21/49
Height (cm)	157.63 ± 8.55
Weight (kg)	61.49 ± 10.34

The values are expressed as mean ± SD or number of patients.

between L and I-T-IC, I-C-IC, or I-IC was assessed by calculating the intraclass correlation coefficient (ICC). Correlations between the L + A and I-T-IC distances and other variables were assessed by using Pearson correlation analysis. Linear regression was performed to develop a model for the predicted L + A on the basis of I-T-IC and patient height. For the final predicted models, a bootstrap analysis was performed: 1000 bootstrap replicates were generated by random sampling from the original data set with replacement. The regression coefficient of the bootstrap bias – corrected prediction equation was estimated by considering bias with samples of 1000 bootstrap replications. All statistical data were analyzed by using SPSS 20.0 (SPSS Inc., Chicago, IL). A p-value less than 0.05 was considered to be statistically significant.

Results

Of the 75 patients who were originally enrolled in this study, three patients changed their minds about participating before the study began, and two patients were excluded because the tip was in an internal jugular vein. As a consequence, the final study cohort comprised 70 subclavian vein catheterizations that were performed with sonographic guidance. The patient characteristics are presented in Table 1.

The mean actual total length of the subclavian catheter (L + A) that was inserted was 14.10 ± 1.46 cm. Table 2 lists the means of L (the length of the catheter between the insertion point of needle and the ipsilateral clavicular notch), the distances of I-IC and I-C-IC, and I-T-IC that were measured on the surface of skin. To determine how well they

Table 2 Distances used to predict the optimal length of subclavian venous cannulation and their agreement with L.

Measurements	Mean ± SD	t-Statistic	p-Value	ICC
L (cm)	92.2 ± 11.6			
I-T-IC (cm)	93.5 ± 11.7	1.45	0.15	0.89
I-C-IC (cm)	114.0 ± 15.5	-17.60	<0.001 ^a	0.28
I-IC (cm)	87.6 ± 10.8	-5.64	<0.001 ^a	0.76

The values are expressed as mean ± SD. ICC, intraclass correlation coefficient; L, catheter length from the needle insertion point to the ipsilateral clavicular notch; I-T-IC, the distance from the needle insertion point to the ipsilateral clavicular notch via the top of the subclavian vein; I-C-IC, the distance from the needle insertion point to the ipsilateral clavicular notch via the clavicle; I-IC, the direct distance from the needle insertion point to the ipsilateral clavicular notch.

^a p < 0.05 versus L.

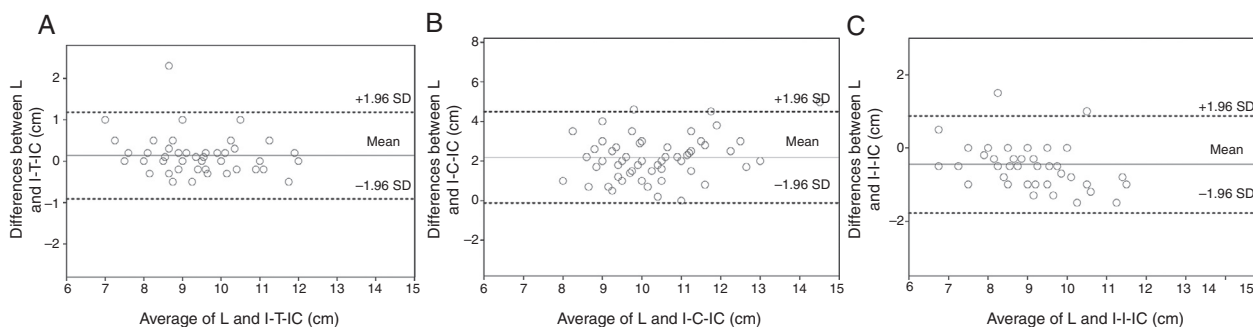


Figure 2 Bland–Altman plots showing the averages and differences between L and I-T-IC (A), I-C-IC (B), or I-IC (C). The mean differences were 0.14, 2.19, and -0.45 cm, respectively. L, the length of the catheter from the needle insertion point to the ipsilateral clavicular notch; I-T-IC, the distance from the needle insertion point to the ipsilateral clavicular notch via the top of the subclavian vein; I-C-IC, the distance from the needle insertion point to the ipsilateral clavicular notch via the clavicle; I-IC, the direct distance from the needle insertion point to the ipsilateral clavicular notch.

predicted optimal subclavian venous cannulation depth, their agreement with L was assessed. The L and the I-T-IC did not differ significantly ($p=0.15$). However, L differed significantly from both I-C-IC ($p < 0.001$) and I-IC ($p < 0.001$). Bland–Altman plots demonstrated large variations in the differences between L and I-IC and between L and I-C-IC. The mean differences between L and I-T-IC, I-C-IC, or I-IC were 0.14, 2.19, and -0.45 cm, respectively. The differences between I-T-IC and L were smaller than the differences between L and I-IC and between L and I-C-IC (Fig. 2).

The mean difference between I-T-IC and L was 0.14 cm [95% confidence interval (CI) 0.01, 0.26], and the ICC of agreement was 0.89 (95% CI 0.83, 0.93). The mean difference between I-C-IC and L was 2.19 cm (95% CI 1.91, 2.47), and the ICC of agreement was 0.28 (95% CI -0.09 , 0.62). The mean difference between I-IC and L was -0.45 cm (95% CI -0.61 , -0.29), and the ICC of agreement was 0.76 (95% CI 0.46, 0.88). The ICC values listed in Table 2 indicate that the I-T-IC distance tended to be the most similar to L.

The total insertion length of subclavian venous catheter (L+A distance in Fig. 1) correlated significantly with I-T-IC ($r=0.78$, $p < 0.0001$), patient age ($r=-0.72$, $p=0.55$), weight ($r=0.11$, $p=0.36$), and height ($r=0.36$, $p=0.002$).

Using linear regression, the following formula was devised to predict L+A:

Predicted L+A (cm) = $-0.037 + 0.036 \times \text{Height}$ (cm) + $0.903 \times \text{I-T-IC}$ (cm), adjusted $r^2 = 0.64$.

Fig. 3 showed that the L+A values predicted by this formula related to the observed L+A value.

None of the patients showed any complications during the determination of the I-IC, I-T-IC, I-C-IC, and L distances, nor during or after right subclavian vein cannulation.

Discussion

Of the three anatomic landmarks investigated here, only the I-T-IC distance successfully predicted the optimal subclavian venous catheter length, which suggests that it may be a useful bedside predictor of the correct catheter insertion length that is to be used during right subclavian venous cannulation. Moreover, by using a formula based on I-T-IC and height, the optimal right subclavian venous catheter insertion length could be predicted without having to make a chest radiograph.

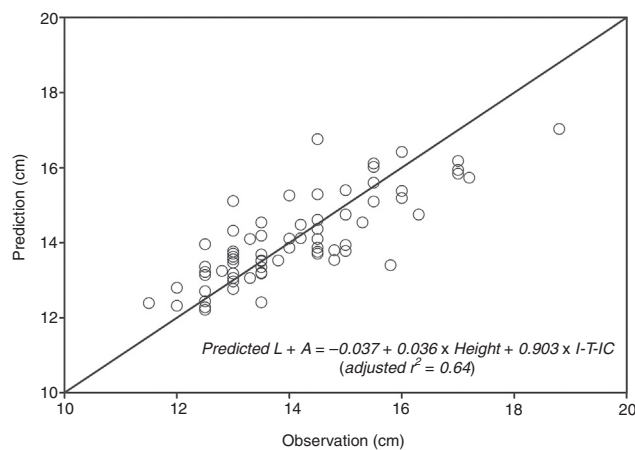


Figure 3 Relationship between the total insertion length predicted by the following formula and the observed total insertion length (L+A). Predicted L+A (cm) = $-0.037 + 0.036 \times \text{Height} + 0.903 \times \text{I-T-IC}$ (adjusted $r^2 = 0.64$). I-T-IC, the distance from the needle insertion point to the ipsilateral clavicular notch via the top of the subclavian vein.

There are no gold standards for predicting the optimal length of catheter insertion during subclavian venous cannulation. To determine the optimal insertion length of the central venous catheter, several landmarks,^{1,2} simple formulas,³ and electrocardiography⁴ have been used. However, for subclavian venous cannulations, such confirmatory techniques are of limited use.

Fletcher et al. suggested that central venous catheter tips should lie above the pericardial reflection.⁹ If central venous catheter tip lies below the pericardial reflection, patients have potentially fatal risk of pericardial tamponade because the central venous catheter tip can penetrate through the vessel wall. Besides, central venous catheter placement in the right atrium can make arrhythmias, narrowing or blocking the coronary sinus, and damage of tricuspid valve. If the central venous catheter tip lies above the pericardial reflection, patients can undergo hydromediastinum or hydrothorax due to extravasated fluid. And patients with central venous catheter tip that lies above the pericardial reflection suffer the superior vena cava damage

more frequently than catheter tip placed below the pericardial reflection.^{10,11} And an angle of the central venous catheter tip to vessel wall and the type of fluid infused can lead to vessel erosion, pain on injection of drugs, infection, and thrombosis.^{12,13}

Topographic landmarks, including the angle of Louis¹⁴ and the right third intercostal space¹⁵ have been used to guide the correct positioning of the subclavian venous catheter tip. Both of them are related to the horizontal plane of the tracheal carina.⁶ In the previous studies, formulas^{12,13,16} using patient height or skin-to-vein distance also recommended. While the techniques based on both of these landmarks are easy to use without any potential complications, they can also be affected by anatomical variation between patients and radiological and physical landmarks, and patient's height, simultaneously.

Kim et al.¹⁷ showed that the optimal catheter insertion length during right subclavian venous cannulation was 12.9 ± 0.9 cm, while Ryu et al.⁵ suggested that 13.8 cm (10.5–18.0 cm) of subclavian venous catheter insertion would be optimal when the infra-clavicular landmark approach was used. However, this fixed length does not consider height, the preferred insertion point of the practitioner, or the method of subclavian venous cannulation, all of which might influence the final location of the catheter tip.

To determine the optimal insertion length of the central venous catheter, electrocardiography⁴ (ECG) was performed. The peak P-wave is usually observed when the central venous catheter tip was placed at the superior vena cava/right atrium junction. At about 4.0 cm above the superior vena cava/right atrium junction, the P-wave returns to a normal shape and size.⁴ Moreover, a transesophageal echocardiography guidance of central venous catheter placement may also effectively be conducted. However, both of these techniques need additional equipment and are potentially associated with increased costs and risks of further complications.^{18,19}

A previous study¹ has shown that the carina was suggested to be a reliable landmark for determining the most appropriate and safest position of the subclavian venous catheter tip above the pericardial reflection. The advantages of this approach include the fixation of the carina to connective tissue, which ensures preservation of placement (even under conditions of pulmonary pathology) and a reduced risk of cardiac tamponade. Thus, this landmark was also used in the present study. Notably, the internal jugular vein and the subclavian vein can be found easily beneath the ipsilateral clavicular notch, which is the site of articulation with the sternal end of the clavicle and can be readily palpated by hand.^{6,20} Therefore, in another study,⁵ the carina served as a landmark of adequate subclavian vein insertion length together with an estimate of the insertion length, which was calculated on the basis of a chest radiograph taken before central venous catheter insertion by adding (i) the distance between the insertion point of needle to the ipsilateral clavicular notch to (ii) the vertical distance between the ipsilateral clavicular notch to the carina. However, this method has some limitations. First, a chest radiograph is needed to evaluate the vertical distance between the ipsilateral clavicular notch and the carina. Second, the subclavian vein follows a curved path: the axillary

vein extends from the axillary area, through either above or below the clavicle, to beneath the ipsilateral clavicular notch.⁶ Thus, the distance between the insertion point of needle and the ipsilateral clavicular notch may be shorter than the optimal insertion length. The vertical distance between the carina and the ipsilateral clavicular notch may be too short because the subclavian vein is curved and practitioner tried with various insertion point as their proper and technique. Thus, the use of the vertical distance between the ipsilateral clavicular notch and the carina can result in subclavian venous catheter malposition and can even cause complications. In the present study, the I-IC values were significantly shorter than L. It should be noted that the use of ultrasound to determine the highest point of the subclavian vein can also be challenging sometimes.

In the present study, the subclavian vein was cannulated by using a sonography-guided longitudinal approach. If the usual the infra-clavicular landmark-guided technique is used, it could lead to puncture of the posterior wall of the subclavian vein, which lies extremely close to the lung apex. However, by using the sonography-guided longitudinal approach, the preferred puncture site in the axillary vein (rather than the subclavian vein) is punctured easily, which can decrease the likelihood of pneumothorax.⁷ Moreover, the axillary venous puncture between the subclavius muscle and the costoclavicular ligament complex decreases the likelihood of trapping the catheter.²¹ It should be noted, however, that the sonography-guided longitudinal approach can lead to more variable subclavian venous catheter lengths than the infra-clavicular landmark technique because the insertion point may vary depending on the practitioner; moreover, axillary vein puncture means that a longer length of curved vein is involved. To compensate for this, the I-T-IC distance was measured in the present study. Indeed, of the various distances that were measured, the I-T-IC distance was found to be the most similar to the actual length.

The I-T-IC distance has some limitations. It is sometimes difficult to identify the top of the subclavian vein because the top of the subclavian vein can be hidden beneath the clavicle; thus, skill is required to find this landmark. In addition, the A distance must be measured on the basis of a chest radiography. Therefore, a formula to predict L + A was calculated on the basis of I-T-IC and height alone. This formula could be used to identify the optimal insertion length in some situations.

In conclusion, the I-T-IC distance may enable reliable bedside prediction of the best optimal insertion length of a right subclavian vein catheter, even when sonographic guidance is used to place the catheter.

Conflicts of interest

The authors declare no conflicts of interest.

Acknowledgements

We would like to thank Seon-Ok Kim, MS. in the Department of Clinical Epidemiology and Biostatistics, Asan Medical Center (Seoul, Korea) for valuable contributions to statistical analysis.

References

1. Schuster M, Nave H, Piepenbrock S, et al. The carina as a landmark in central venous catheter placement. *Br J Anaesth.* 2000;85:192–4.
2. Stonelake PA, Bodenham AR. The carina as a radiological landmark for central venous catheter tip position. *Br J Anaesth.* 2006;96:335–40.
3. Chalkiadis GA, Goucke CR. Depth of central venous catheter insertion in adults: an audit and assessment of a technique to improve tip position. *Anaesth Intensive Care.* 1998;26:61–6.
4. Jeon Y, Ryu HG, Yoon SZ, et al. Transesophageal echocardiographic evaluation of ECG-guided central venous catheter placement. *Can J Anaesth.* 2006;53:978–83.
5. Ryu HG, Bahk JH, Kim JT, et al. Bedside prediction of the central venous catheter insertion depth. *Br J Anaesth.* 2007;98:225–7.
6. Ellis H, Dussek JE. Surface anatomy. In: PL W, editor. *Gray's anatomy.* 38th ed. New York: Churchill Livingstone; 1995. p. 1916.
7. Mauro MA, Jaques PF. Radiologic placement of long-term central venous catheters: a review. *J Vasc Interv Radiol.* 1993;4:127–37.
8. Machi J, Takeda J, Kakegawa T. Safe jugular and subclavian venipuncture under ultrasonographic guidance. *Am J Surg.* 1987;153:321–3.
9. Fletcher SJ, Bodenham AR. Safe placement of central venous catheters: where should the tip of the catheter lie? *Br J Anaesth.* 2000;85:188–91.
10. Tocino IM, Watanabe A. Impending catheter perforation of superior vena cava: radiographic recognition. *AJR Am J Roentgenol.* 1986;146:487–90.
11. Duntley P, Siever J, Korwes ML, et al. Vascular erosion by central venous catheters. Clinical features and outcome. *Chest.* 1992;101:1633–8.
12. Raad II, Luna M, Khalil SA, et al. The relationship between the thrombotic and infectious complications of central venous catheters. *JAMA.* 1994;271:1014–6.
13. Cadman A, Lawrance JA, Fitzsimmons L, et al. To clot or not to clot? That is the question in central venous catheters. *Clin Radiol.* 2004;59:349–55.
14. Ezri T, Weisenberg M, Sessler DI, et al. Correct depth of insertion of right internal jugular central venous catheters based on external landmarks: avoiding the right atrium. *J Cardiothorac Vasc Anesth.* 2007;21:497–501.
15. Kim KO, Jo JO, Kim HS, et al. Positioning internal jugular venous catheters using the right third intercostal space in children. *Acta Anaesthesiol Scand.* 2003;47:1284–6.
16. Peres PW. Positioning central venous catheters – a prospective survey. *Anaesth Intensive Care.* 1990;18:536–9.
17. Kim MC, Kim KS, Choi YK, et al. An estimation of right- and left-sided central venous catheter insertion depth using measurement of surface landmarks along the course of central veins. *Anesth Analg.* 2011;112:1371–4.
18. Wilson RG, Gaer JA. Right atrial electrocardiography in placement of central venous catheters. *Lancet.* 1988;1:462–3.
19. Andropoulos DB, Stayer SA, Bent ST, et al. A controlled study of transesophageal echocardiography to guide central venous catheter placement in congenital heart surgery patients. *Anesth Analg.* 1999;89:65–70.
20. Soames RW. Skeletal system. In: Williams PL, editor. *Gray's anatomy.* New York: Churchill Livingstone; 1995. p. 537.
21. Krutchen AE, Bjarnason H, Stackhouse DJ, et al. The mechanisms of positional dysfunction of subclavian venous catheters. *Radiology.* 1996;200:159–63.