



# REVISTA BRASILEIRA DE ANESTESIOLOGIA

Publicação Oficial da Sociedade Brasileira de Anestesiologia  
[www.sba.com.br](http://www.sba.com.br)



## REVIEW ARTICLE

# Marfan Syndrome: new diagnostic criteria, same anesthesia care? Case report and review



María Rita Araújo\*, Céline Marques, Sara Freitas, Rita Santa-Bárbara, Joana Alves, Célia Xavier

Anesthesiology Department, Hospital Santa Maria, Lisbon, Portugal

Received 16 August 2014; accepted 8 September 2014

Available online 27 November 2014

### KEYWORDS

Marfan Syndrome;  
General anesthesia;  
Perioperative care

### Abstract

**Background:** Marfan's Syndrome (MFS) is a disorder of connective tissue, mainly involving the cardiovascular, musculoskeletal, and ocular systems. The most severe problems include aortic root dilatation and dissection. Anesthetic management is vital for the improvement on perioperative morbidity.

**Case report:** 61-year-old male with MFS, presenting mainly with pectus carinatum, scoliosis, ectopia lens, previous spontaneous pneumothorax and aortal aneurysm and dissection submitted to thoracoabdominal aortic prosthesis placement. Underwent routine laparoscopic cholecystectomy due to lithiasis. Important findings on preoperative examination were thoracolumbar kyphoscoliosis, metallic murmur on cardiac exam. Chest radiograph revealed Cobb angle of 70°. Echocardiogram showed evidence of aortic mechanical prosthesis with no deficits.

**Discussion:** Preoperative evaluation should focus on cardiopulmonary abnormalities. The anesthesiologist should be prepared for a potentially difficult intubation. Proper positioning and limb support prior to induction is crucial in order to avoid joint injuries. Consider antibiotic prophylaxis for subacute bacterial endocarditis. The patient should be carefully positioned to avoid joint injuries. Intraoperatively cardiovascular monitoring is mandatory: avoid maneuvers that can lead to tachycardia or hypertension, control airway pressure to prevent pneumothorax and maintain an adequate volemia to decrease chances of prolapse, especially if considering laparoscopic surgery. No single intraoperative anesthetic agent or technique has demonstrated superiority. Adequate postoperative pain management is vitally important to avoid the detrimental effects of hypertension and tachycardia.

© 2014 Sociedade Brasileira de Anestesiologia. Published by Elsevier Editora Ltda. This is an open access article under the CC BY-NC-ND license (<http://creativecommons.org/licenses/by-nc-nd/4.0/>).

\* Corresponding author.

E-mail: [m.rita.araujo@gmail.com](mailto:m.rita.araujo@gmail.com) (M.R. Araújo).

**PALAVRAS-CHAVE**

Síndrome de Marfan;  
Anestesia geral;  
Cuidados  
pré-operatórios

## Síndrome de Marfan: novos critérios diagnósticos, mesma abordagem anestésica? Relato de caso e revisão

**Resumo**

**Justificativa:** A síndrome de Marfan (SMF) é uma doença do tecido conjuntivo que envolve principalmente os sistemas: cardiovascular, músculo-esquelético e visual. Os problemas mais graves incluem dilatação da raiz da aorta e dissecação. O manejo anestésico é vital para a melhora da morbidade perioperatória.

**Relato de caso:** Homem de 61 anos com SMF, apresentando-se principalmente com *pectus carinatum*, escoliose, ectopia da lente, pneumotórax e espontâneo anterior e aneurisma da aorta e dissecação, submetido à colocação de prótese aórtica toracoabdominal. O paciente foi submetido à colecistectomia videolaparoscópica de rotina devido à litíase. Os achados importantes ao exame pré-operatório foram cifoescoliose tóracolombar e murmúrio metálico em exame cardíaco. A radiografia de tórax revelou ângulo de Cobb de 70° e o ecocardiograma mostrou evidência de prótese mecânica aórtica sem alterações.

**Discussão:** A avaliação pré-operatória deve ter como foco as anormalidades cardiopulmonares. O anestesiológista deve estar preparado para uma intubação potencialmente difícil. O posicionamento adequado e apoio para o membro antes da indução são fundamentais para evitar lesões nas articulações. Profilaxia antibiótica deve ser considerada para endocardite bacteriana subaguda. O paciente deve ser cuidadosamente posicionado para evitar lesões das articulações. O monitoramento cardiovascular é obrigatório no período intraoperatório: evitar manobras que podem levar à taquicardia ou hipertensão; controlar a pressão das vias aéreas para evitar pneumotórax e manter uma volemia adequada para diminuir as chances de prolapse, especialmente em caso de laparoscopia. Nenhum agente anestésico ou técnica demonstrou superioridade no período intraoperatório. O tratamento adequado da dor no pós-operatório é de vital importância para evitar os efeitos deletérios da hipertensão e taquicardia.

© 2014 Sociedade Brasileira de Anestesiologia. Publicado por Elsevier Editora Ltda. Este é um artigo Open Access sob uma licença CC BY-NC-ND (<http://creativecommons.org/licenses/by-nc-nd/4.0/>).

**Introduction**

The MFS (MFS) is an autosomal dominant condition caused by a mutation in the FBN1 gene on chromosome 15 that encodes the protein fibrillin. This defect results in a set of expressions of various organs and systems, being musculoskeletal, cardiovascular and ophthalmic manifestations the most notorious.

It has an estimated incidence of 2–3 per 10,000 inhabitants.<sup>1</sup>

In 2010 the Ghent Nosology was revised, and new diagnostic criteria superseded the previous agreement made in 1996. The seven new criteria can lead to a diagnosis, being necessary to fulfill just one of the criteria:<sup>2</sup>

In the absence of a family history:

1. Aortic root Z-score  $\geq 2$  + *ectopia lentis*
2. Aortic root Z-score  $\geq 2$  + FBN1 mutation
3. Aortic root Z-score  $\geq 2$  + systemic score  $> 7$  points
4. *Ectopia lentis* AND an FBN1 mutation with known aortic pathology

In the presence of a family history:

1. *Ectopia lentis*
2. Systemic score  $\geq 7$
3. Aortic root Z-score  $\geq 2$

Points for systemic score:

Wrist AND thumb sign = 3 (wrist OR thumb sign = 1)

*Pectus carinatum* deformity = 2 (*pectus excavatum* or chest asymmetry = 1)

Hindfoot deformity = 2 (*pes planus* = 1)

Dural ectasia = 2

*Protrusio acetabuli* = 2

Reduced upper segment/lower segment ratio AND increased arm/height AND no severe scoliosis = 1

Scoliosis or thoracolumbar kyphosis = 1

Reduced elbow extension = 1

Facial features (3/5) = 1 (dolichocephaly, enophthalmos, downslanting palpebral fissures, malar hypoplasia, retrognathia) Skin striae = 1

Myopia  $> 3$  diopters = 1

Mitral valve prolapse = 0.25

In 1972, the decrease in average life expectancy in these patients was due to the changes on cardiovascular system, aortic aneurysm rupture being the major cause of mortality.<sup>3</sup>

In 2010 life expectancy for patients with MFS has increased  $> 25\%$  since 1972. Reasons to sustain this dramatic increase may include benefits arising from cardiovascular surgery, and greater proportion of milder cases due to increased frequency of diagnosis. Medical therapy (including beta blockers) was also associated with an increase in probable survival.<sup>4</sup>

The potential risk of cardiac and respiratory events in a patient with MFS justifies the importance of an opportune

and thorough pre-anesthetic assessment, along with the use of the most appropriate anesthetic techniques.

The 2010 revised criteria classified 83% of the patients with a mutation in *FBN1* as having MFS, compared with 89% according to the older criteria.<sup>5</sup> There are a number of conditions of the connective tissue with a similar phenotype that can be confused with MFS, and the recently published modifications of the diagnostic criteria facilitate the differentiation of MFS from these conditions.<sup>6</sup> The focus has shifted from the musculoskeletal signs to the cardiovascular and ocular abnormalities. Thus, the presence of a dilated aorta plus *ectopia lentis* is now sufficient to give an unequivocal diagnosis of MFS. In the previous criteria, involvement of a third system or the patient having an affected family member was also required for diagnosis.

## Case report

We present a 61-year-old male, 105 kg, 195 cm, with MFS fulfilling the following diagnosis criteria, according to the new classification:

- Absence of family history
- Aortic root Z-score =  $-1.91$  (not achieving criteria)
- *Pectus carinatum*
- Scoliosis  $>20^\circ$
- Walker–Murdoch sign; thumb sign (Fig. 1), planuvalgus foot (Fig. 2)
- Characteristic facial appearance
- Aneurysm of thoracoabdominal aorta with involvement of the ascending segment and aortic arch, associated with type B dissection of descending thoracic aorta, involving the ascending, descending and aortic arch. Submitted to supracoronary replacement and total aortic conduit on an innovative and high risk surgery on Oxford Heart Center;<sup>7</sup> nowadays presents with type A aortic dissection (ascending and arch), celiac trunk aneurysm, under imagiological follow-up and ectasia of the right primitive iliac artery with partial lumen thrombosis
- Lens extraction due to ectopia in 1978
- Retinal detachment in 1993
- Spontaneous right pneumothorax in 1999

This means that this patient does not meet the criteria for diagnosis of MFS, according to the revised Ghent Nosology.

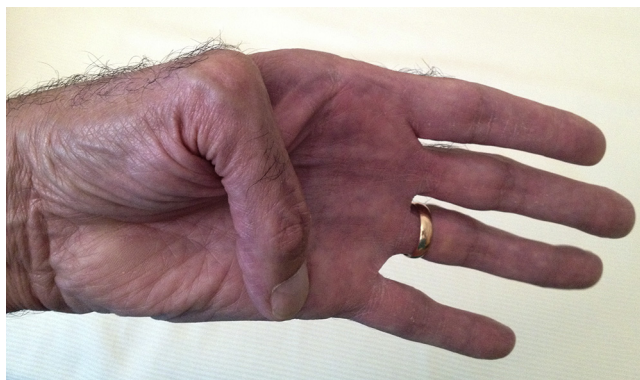

Figure 1 Murdoch sign.

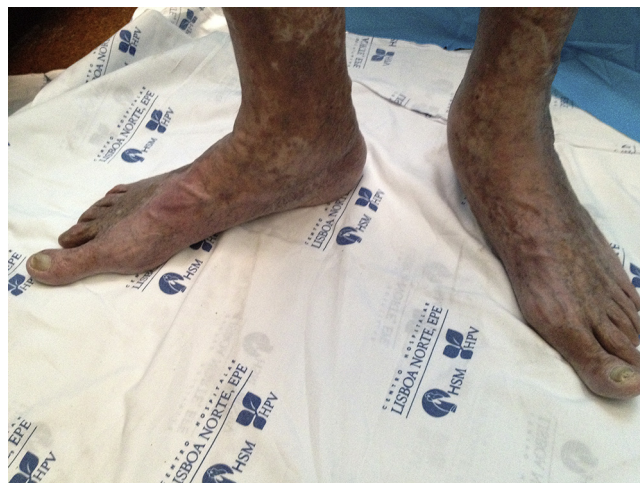

Figure 2 Planuvalgus foot.

However the patient has other associated co-morbidities:

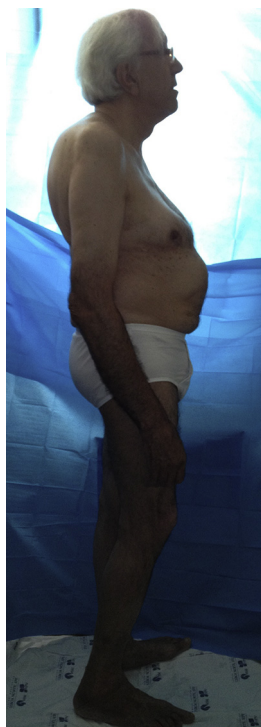
- Superficial venous insufficiency
- Inaugural episode of Atrial Fibrillation in 2009 with conversion to sinus rhythm after loading dose of amiodarone
- Bilateral Pulmonary emphysema associated with pleural effusion
- Iodine contrast allergy
- Chronic hypertension, with Class III NYHA grade for cardiac failure
- Inguinal hernioplasty in 1984

The patient was medicated with warfarin (suspended five days before admission fulfilling bridging with enoxaparin in therapeutic dose), omeprazole 20 mg/day, carvedilol 25 mg/day, ramipril 5 mg/day and losartan 50 mg/day.

Physical examination revealed the following: HR 70 bpm regular, BP 128/73 mmHg; Oral cavity with low arched palate and slight retrognathia which anticipated a potential difficult intubation (Figs. 3 and 4); Inter-incisor distance  $>3$  cm; thyromentonian length  $>6$  cm, Mallampati 1; No deformation or cervical tumors; No neck movement limitations; Evidence of thoracolumbar kyphoscoliosis in Adams test (Fig. 5); Heart sounds preserved with metallic murmur due to aortic prosthesis; and Decreased breath sound at bases with *subcrepitant rhonchus*.

From the preoperative complementary evaluation performed, the analytical study showed no significant changes (Hb 14.4 g/dL; 117,000 platelets, INR 1.1, Cr 0.88 mg/d,  $K^+$  3.8 mmol/L); ECG on sinus rhythm with HR 60 bpm; chest radiograph with extensive hilar, perihilar and bilateral reticular infiltrates, as well as thoracic scoliosis, convex to the right, with Cobb angle  $\approx 70^\circ$  (Fig. 6), pulmonary function tests with moderate to severe mixed abnormality and negative methacholine challenge test; Echocardiogram with evidence of normofunctioning mechanical prosthesis in aortic position. Slight biauricular dilation; spPa increased (34 mmHg). CT angiogram shows the reconstruction of thoracoabdominal aortic conduit, also evident in MRI angiography performed (Figs. 7 and 8).





**Figure 3** Oral cavity with low arched palate.

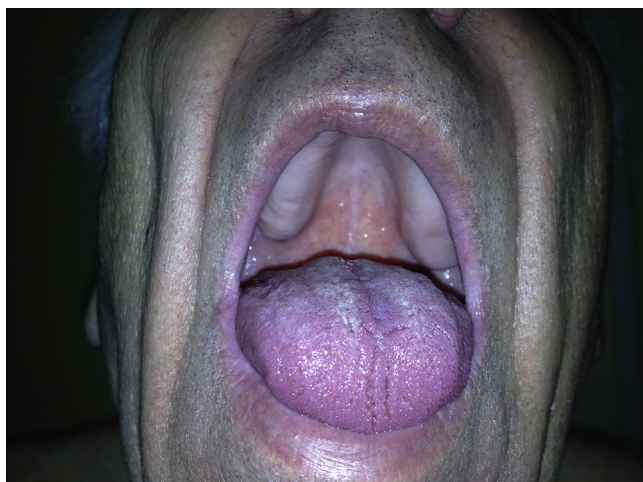
The patient was submitted to laparoscopic cholecystectomy under general anesthesia.

He was premedicated with Hydroxyzine 25 mg PO on the day before and 25 mg PO on the day of the surgery, associated with lorazepam in the same scheme and enoxaparin in therapeutic dose (last dose 12 h before surgery). Antibiotic prophylaxis was carried out with 2 g of cefazolin IV + Gentamycin 80 mg IV and prophylaxis of stress peptic ulcer with esomeprazole 40 mg IV.

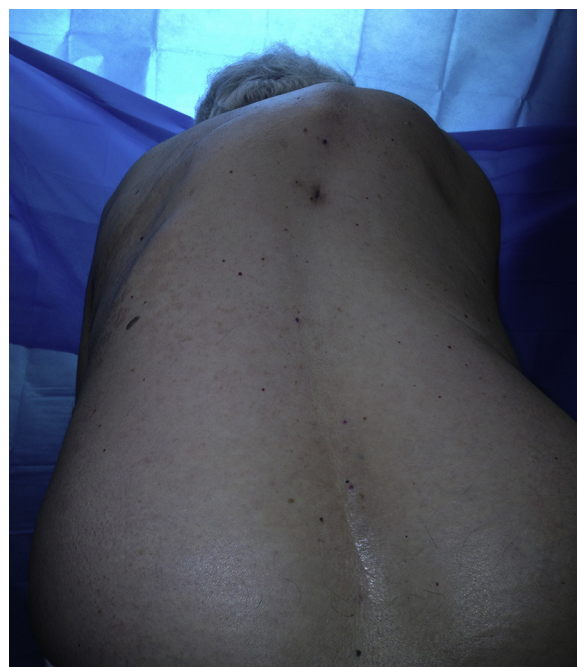Monitoring with pulse oximeter, noninvasive BP, electrocardiography and capnography was started.

Two peripheral IV lines of high caliber were secured, with local anesthesia (20G MSE and 16G MSE).

Preoxygenation was performed with 100% O<sub>2</sub> for 4 min.



**Figure 4** Oral cavity with slight retrognathia.



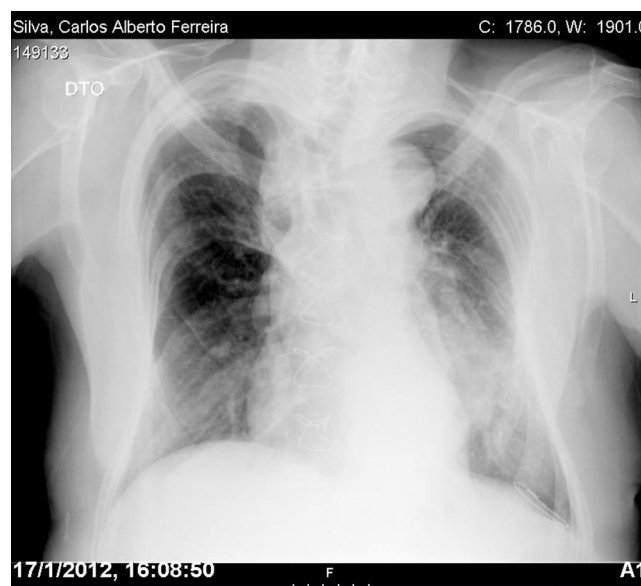
**Figure 5** Thoracolumbar kyphoscoliosis in Adams test.

Anesthesia was induced with remifentanyl, 200 mg of propofol and 50 mg of rocuronium. The patient was ventilated with a facemask with 100% O<sub>2</sub> for 2 min, before being intubated by direct laryngoscopy without difficulty (Cormack-Lehane Index 1).

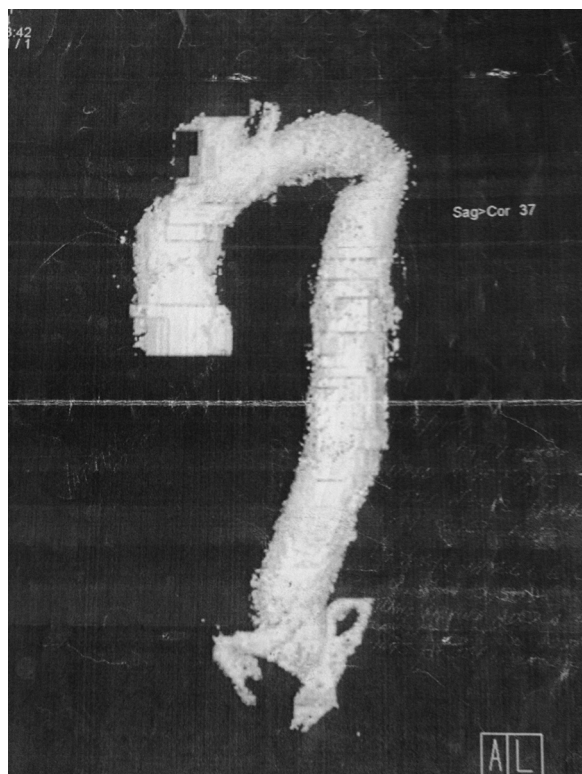
The patient was ventilated in controlled volume and anesthesia was maintained with sevoflurane and remifentanyl perfusion.

Postoperative nausea and vomiting prophylaxis was performed with droperidol 1.25 mg and dexamethasone 8 mg.

The surgery proceeded uneventfully and lasted for 1 h.



**Figure 6** Thoracic scoliosis, convex to the right, with Cobb angle  $\approx 70^\circ$ .

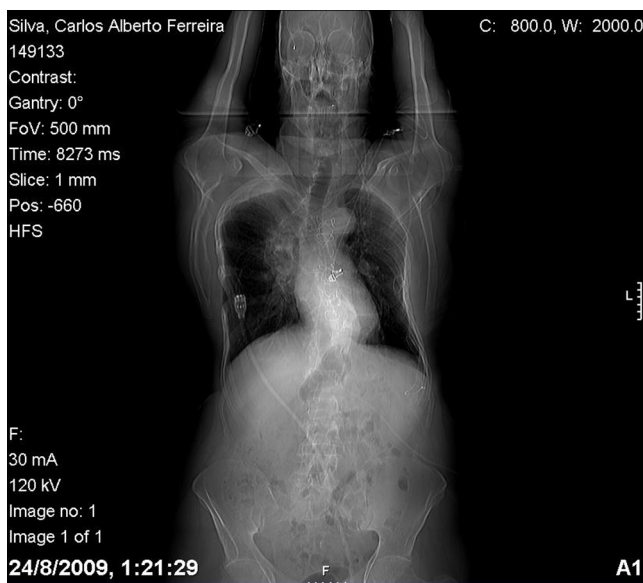

**Figure 7** CT angiogram shows the reconstruction of thoracoabdominal aortic conduit.

Reversion of neuromuscular blockade was made with 2.5 mg of neostigmine and 1 mg of atropine and the extubation progressed uneventfully.

Analgesia was achieved with Paracetamol, Metamizol and morphine 24 mg/day.

The patient was discharged on the 3rd postoperative day without complaints or record of complications.



**Figure 8** MRI angiography performed.

## Discussion

New diagnostic criteria for MFS give more emphasis to aortic root aneurysm and *ectopia lentis*, with or without family history or positive FBN1 gene test leaving the systemic features on the backburner.<sup>8</sup> This patient has a Z-Score (after surgical correction) of  $-1.99$ , fulfilling several systemic points for MFS diagnosis. Proper diagnosis is crucial for the appropriate evaluation of the patient and to avoid predictable and potentially fatal complications such as rupture of an aortic aneurysm. The new diagnostic criteria, not organized on organ systems, strengthen the role of the anesthesiologist on performing careful evaluation of the potential organs involved.

On physical examination, one should be alert to signs of congestive heart failure. Cardiovascular functional status needs to be assessed, including ECG, cardiac catheterization, MRI and echocardiography as indicated to access the size of the aortic root and valvular function. In this case report, the metallic murmur was due to aortic prosthesis placed on previous surgery. Nevertheless, an echocardiogram was performed and revealed a preserved function. Regarding lung function, MFS patients normally present with restrictive ventilatory defects, not only because of the underlying emphysema, but also due to the musculoskeletal changes that affect thoracic expansion.<sup>9</sup> The patient has a scoliosis degree greater than 20 which justifies his described ventilatory changes.

Strict preoperative control of blood pressure is vitally important to minimize shear forces and wall stress in the aorta to decrease the risk of aortic rupture or dissection. Perioperative maintenance of beta-blocker<sup>10</sup> is recommended in order to reduce myocardial contractility and control aortic wall tension. In the case of this patient, given the existence of an aortic mechanical prosthesis and thoraco-abdominal aortic conduit, the control of vascular wall tension is imperative, especially with the evidence of a chronic type B aortic dissection. Recent studies suggest benefit of vasodilator beta-blockers to control hypertension in MFS patients.<sup>11</sup> Patients needing additional medications to control blood pressure, especially those with chronic dissections, might be treated with an angiotensin receptor blocker in addition to  $\beta$ -blockade.<sup>8</sup>

In patients with valve replacements, antibiotic prophylaxis and warfarin bridging should be carried out timeously, as was in this case report.<sup>12</sup>

Proper positioning and limb support must be assured, considering the ligamentous *hyperlaxity* and increased risk of joint damage.

The anesthesiologist should be prepared for a potentially difficult intubation owing to factors related with arched palate, retrognathia and ligamentous *hyperlaxity*<sup>13</sup> that can lead to joint luxation during neck extension (cervical spine, tempuromandibular).

Intraoperative cardiovascular monitoring is the core concern: laryngoscopy should be as smooth as possible to prevent hypertension and subsequently increased risk of dissection. Other maneuvers or drugs that may lead to tachycardia or hypertension should be avoided. Changes on AV conduction or perioperative dysrhythmias are common, but not verified on this specific case report. Ventilatory pressures must be kept as low as possible to prevent

barotrauma and reduce the risk of pneumothorax, especially if the patient has a previous diagnosis of lung cysts. Tracheomalacia has been reported as a potential complication.<sup>14</sup> In this case, the patient had a history of spontaneous pneumothorax that alone increases the risk of a new pneumothorax even if pleurodesis was performed.<sup>15</sup> This fact, associated with the trendelenburg position and increased intra-abdominal pressure inherent to laparoscopic surgery, increase the likelihood of developing pneumothorax. As for intraoperative fluid therapy, the primary goal is to maintain blood volume in order to decrease the chances of aortic and/or mitral valve prolapse. There is no anesthetic technique that has proven more effective. The induction, maintenance and recovery of anesthesia and postoperative analgesia are kept at the discretion of the anesthesiologist, always paying attention to cardiovascular balance.<sup>16</sup>

## Conclusion

In conclusion, the preexisting cardiovascular disease and the potential for acute cardiovascular and respiratory complications in patients with MFS demand careful preoperative assessment and the use of skillful anesthetic technique to avoid fatal complications. Blood pressure control is the central component of perioperative management. The risk of perioperative morbidity and mortality, including unexplained death, is high.<sup>17</sup>

The new revised criteria decrease the range of MFS diagnosis in patients with positive phenotype but minimal aortic root dilatation. But phenotype changes, as well as borderline aortic root dilatation, even without a definite diagnosis, influence the conduct of the anesthesiologist on the perioperative and intraoperative period as described above.

Lastly, an anesthesiologist should complement the new revised criteria with the old classification to prevent perioperative important morbidity on a patient that has positive diagnosis according to old criteria, but not according to new criteria.

## Conflicts of interest

The authors declare no conflicts of interest.

## Acknowledgements

The authors are grateful to Anesthesia Department of Santa Maria Hospital for all the records provided. They would also like to thank all the study participants, especially Dr. Célia Xavier, for valuable discussions.

## References

1. Ammash N, Sundt T. MFS-diagnosis and management. *Curr Probl Cardiol.* 2008;33:7–39.
2. 2010 revised Ghent nosology. National Marfan Foundation; 2011. <http://www.marfan.org/dx/revised-ghent-nosology>
3. Murdoch J, Walker BA, Halpern BL, et al. Life expectancy and causes of death in the MFS. *N Engl J Med.* 1972;286:804.
4. Silverman D, Burton KJ, Gray J, et al. Life expectancy in the MFS. *Am J Cardiol.* 1995;15:157–60.
5. Faivre L, Colod-Beroud G, Adès L, et al. The new Ghent criteria for MFS: what do they change? *Clin Genet.* 2012;81:433–42.
6. Summers KM, West JA, Peterson MM, et al. Challenges in the diagnosis of MFS. *Med J Aust.* 2006;184:627–31.
7. Westaby S. Aortic dissection in MFS. *Ann Thorac Surg.* 1999;67:1861–3.
8. Loeys BL, Dietz H, Braverman A, et al. The revised Ghent nosology for the MFS. *J Med Genet.* 2010;47:476–85.
9. Streeten EA. Pulmonary function in the MFS. *Chest.* 1987;91:408–12.
10. Keane M, Pyeritz E. Medical management of MFS. *Circulation.* 2008;117:2802–13. Role of beta-blockers in Marfan's Syndrome and bicuspid aortic valve: a time for re-appraisal.
11. Koračević G, Saka D, Pavlovi M, et al. Should we prescribe "vasodilating" beta-blockers in MFS to prevent aortic aneurysm and dissection? *Vojnosanit Pregl.* 2012;69:195–200.
12. Pagon RA, Adam M, Ardinger H, et al. *MFS. GeneReviews™.* Seattle, WA: University of Washington; 1993–2013.
13. Grahame R, Pyeritz RE. MFS: joint and skin manifestation are prevalent and correlated. *Br J Rheumatol.* 1995;34:126–31.
14. OH AY, Kim YH, Kim BK, et al. Unexpected tracheomalacia in MFS during general anesthesia for correction of scoliosis. *Anesth Analg.* 2002;95:331–5.
15. Steward DJ. *Manual of pediatric anesthesia.* New York: Churchill Livingstone; 1979. p. 246–7.
16. Hines RL, Marschall KE. *Stoleting's anesthesia and co-existing disease,* 5th ed. Philadelphia, PA: Elsevier; 2008. p. 33–4, 136–137.
17. Verghese C. Anesthesia in Marfan's Syndrome. *Anaesthesia.* 1984;39:917–22.