



# REVISTA BRASILEIRA DE ANESTESIOLOGIA

Publicação Oficial da Sociedade Brasileira de Anestesiologia  
www.sba.com.br



## SCIENTIFIC ARTICLE

# Evaluation of the effects of intra-arterial sugammadex and dexmedetomidine: an experimental study



Volkan Hancı<sup>a,\*</sup>, Şule Özbilgin<sup>b</sup>, Seda Özbal<sup>b</sup>, Gonca Kamacı<sup>c</sup>, Hasan Ateş<sup>d</sup>, Nilay Boztaş<sup>a</sup>, Bekir Uğur Ergür<sup>b</sup>, Ahmet Arıkanoglu<sup>a</sup>, Osman Yılmaz<sup>c</sup>, Bülent Serhan Yurtlu<sup>a</sup>

<sup>a</sup> Dokuz Eylül University, School of Medicine, Department of Anesthesiology and Reanimation, İnciraltı, İzmir, Turkey

<sup>b</sup> Dokuz Eylül University, School of Medicine, Department of Histology and Embryology, İnciraltı, İzmir, Turkey

<sup>c</sup> Dokuz Eylül University, School of Medicine, Department of Experienced Laboratory Animal Science, İnciraltı, İzmir, Turkey

<sup>d</sup> Dokuz Eylül University, School of Medicine, Department of Plastic, Reconstructive and Aesthetic Surgery, İnciraltı, İzmir, Turkey

Received 20 December 2014; accepted 30 January 2015

Available online 1 October 2015

### KEYWORDS

Sugammadex;  
Dexmedetomidine;  
Intra-arterial;  
Rabbit;  
Experimental

### Abstract

**Background:** Intra-arterial injection of medications may cause acute and severe ischemia and result in morbidity and mortality. There is no information in the literature evaluating the arterial endothelial effects of sugammadex and dexmedetomidine. The hypothesis of our study is that sugammadex and dexmedetomidine will cause histological changes in arterial endothelial structure when administered intra-arterially.

**Methods:** Rabbits were randomly divided into 4 groups. Group Control ( $n=7$ ); no intervention performed. Group Catheter ( $n=7$ ); a cannula inserted in the central artery of the ear, no medication was administered. Group Sugammadex ( $n=7$ ); rabbits were given 4 mg/kg sugammadex into the central artery of the ear, and Group Dexmedetomidine ( $n=7$ ); rabbits were given 1  $\mu$ g/kg dexmedetomidine into the central artery of the ear. After 72 h, the ears were amputated and histologically investigated.

**Results:** There was no significant difference found between the control and catheter groups in histological scores. The endothelial damage, elastic membrane and elastic fiber damage, smooth muscle hypertrophy and connective tissue increase scores in the dexmedetomidine and sugammadex groups were significantly higher than both the control and the catheter groups ( $p<0.05$ ). There was no significant difference found between the dexmedetomidine and sugammadex groups in histological scores.

**Conclusion:** Administration of sugammadex and dexmedetomidine to rabbits by intra-arterial routes caused histological arterial damage. To understand the histological changes caused by sugammadex and dexmedetomidine more clearly, more experimental research is needed.

© 2015 Sociedade Brasileira de Anestesiologia. Published by Elsevier Editora Ltda. This is an open access article under the CC BY-NC-ND license (<http://creativecommons.org/licenses/by-nc-nd/4.0/>).

\* Corresponding author.

E-mail: [vhanci@gmail.com](mailto:vhanci@gmail.com) (V. Hancı).

**PALAVRAS-CHAVE**

Sugammadex;  
Dexmedetomidina;  
Intra-arterial;  
Coelho;  
Experimental

**Avaliação dos efeitos de sugamadex e dexmedetomidina intra-arterial: estudo experimental****Resumo**

*Justificativa:* A injeção intra-arterial de medicamentos pode causar isquemia aguda e grave e resultar em morbidade e mortalidade. Não há informações na literatura avaliando os efeitos endoteliais arteriais de sugamadex e dexmedetomidina. A hipótese de nosso estudo foi que dexmedetomidina e sugamadex causariam alterações histológicas na estrutura endotelial arterial quando administrados por via intra-arterial.

*Método:* Os coelhos foram randomicamente divididos em quatro grupos: grupo controle (n = 7), sem intervenção realizada; grupo cateter (n = 7), uma cânula foi inserida na artéria central da orelha e medicamentos não foram administrados; grupo sugamadex (n = 7), os coelhos receberam 4 mg/kg de sugamadex na artéria central da orelha; grupo dexmedetomidina (n = 7), os coelhos receberam 1 µg/kg de dexmedetomidina na artéria central da orelha. Após 72 horas, as orelhas foram amputadas e histologicamente examinadas.

*Resultados:* Não houve diferença significativa entre os grupos controle e cateter referente aos escores histológicos. Os escores do dano causado ao endotélio e à membrana e fibra elásticas, da hipertrofia do músculo liso e do aumento do tecido conjuntivo foram significativamente maiores nos grupos dexmedetomidina e sugamadex que em ambos os grupos controle e cateter (p < 0,05). Não houve diferença significativa entre os grupos dexmedetomidina e sugamadex nos escores histológicos.

*Conclusão:* A administração de sugamadex e dexmedetomidina a coelhos por via intra-arterial causou danos arteriais histológicos. Para entender as alterações histológicas causadas por sugamadex e dexmedetomidina com mais clareza, estudos experimentais adicionais são necessários. © 2015 Sociedade Brasileira de Anestesiologia. Publicado por Elsevier Editora Ltda. Este é um artigo Open Access sob uma licença CC BY-NC-ND (<http://creativecommons.org/licenses/by-nc-nd/4.0/>).

**Introduction**

Intra-arterial injection of medications may cause acute and severe ischemia and result in morbidity and mortality. The intra-arterial injection and cannulation incidence varies from 1/3440 to 1/56,000. Medications for sedation or general anesthesia, mainly, are mistakenly administered intra-arterially.<sup>1,2</sup> Intra-arterial injection of medications may cause acute and severe ischemia. It is difficult to fully determine the correct incidence of rare situations such as this.<sup>1-3</sup> After the intravenous forms of medications are given through intra-arterial routes, local ischemia and later tissue necrosis may develop in the artery. The physiopathological mechanisms of intra-arterial medication injection and development of ischemia are not clear. Among mechanisms blamed are formation of crystals of medication in small arteries, secondary hemolysis and platelet aggregation after intimal damage, and stasis, thrombosis and direct cytotoxicity in the artery. The tissue damage is essentially determined by the chemical structure and amount of the medication.<sup>1-3</sup>

The pathogenesis of formation of necrosis after intra-arterial injection of medication is not clear.<sup>1,4</sup> The rabbit ear model is a frequently used method to research the pathological process of intra-arterial injections. No matter how visibly different rabbit and human ears are, they are helpful to observe the tissue response to intra-arterial medications.<sup>4</sup>

Sugammadex is a medication newly entering anesthesia practice. It is a cyclodextrine-structured medication that selectively binds to aminosteroid-structure non-depolarizing

muscle relaxants like rocuronium, ending their effects. It shows high selectivity especially for rocuronium and vecuronium. It may enter physicochemical reactions with different medications.<sup>5</sup>

There is no information in the literature evaluating the arterial endothelial effects of sugammadex and dexmedetomidine, two medications newly entering anesthetic practice. Only a single case report was found about dexmedetomidine mistakenly administered intra-arterially.<sup>6</sup>

The hypothesis of our study is that sugammadex and dexmedetomidine will cause histological changes in arterial structure when administered intra-arterially. To test this hypothesis in this planned study we used rabbit ear arteries to intra-arterially inject 4 mg/kg sugammadex and 1 µg/kg dexmedetomidine aiming to research the histological effects.

**Method**

The study was completed in Dokuz Eylül University Medical Faculty experimental animal laboratory after receiving permission from Dokuz Eylül University Medical Faculty Animal Experiments Ethics Committee (Meeting date: 08.01.2014 – Decision number: 115/2013). The research used 28 adult male New Zealand white rabbits weighing from 2.5 to 3 kg. The subjects obtained from DEUMF Experimental Animals Laboratory were fed with standard rabbit feed and water. The rabbits were housed in temperature-controlled (22–24 °C) illuminated rooms (12:12 h light/dark) before the

study. During the experiment international guidelines were maintained for care of laboratory animals.

Using sterile techniques the rabbits in the experimental group were given 50 mg/kg ketamine intraperitoneally. As the animals may have different responses to the anesthetic medications, depth of anesthesia was determined by monitoring palpebra or cornea reflexes.

Our study used the rabbit ear model described by Kinmonth and Sheppard.<sup>7</sup> Rabbits with sufficient anesthesia had intra-arterial intervention with a 24 G cannula.

Rabbits were randomly divided into 4 groups:

Group Control ( $n=7$ ): rabbits in this group had no intervention performed.

Group Catheter ( $n=7$ ): rabbits had a cannula inserted in the central artery of the ear, however no medication was administered.

Group Sugammadex ( $n=7$ ): rabbits were given 4 mg/kg (100 mg/mL) sugammadex into the central artery of the ear, given as bolus within 10 s for a total volume of 2 mL.

Group Dexmedetomidine ( $n=7$ ): rabbits were given 1  $\mu$ g/kg (100  $\mu$ g/mL) dexmedetomidine into the central artery of the ear with loading dose administered with an infusion pump over 10 min for a total volume of 2 mL.

After 72 h, the rabbits in all groups were given 50 mg/kg ketamine intraperitoneally and after anesthesia was provided, the ears were amputated and histologically investigated.

For macroscopic investigation sections especially to evaluate arterial cross-section, samples were fixed in 10% buffered formaldehyde and then submerged in paraffin. Then the prepared paraffin blocks were serially cut to 4  $\mu$ m thickness using a rotary microtome (Leica RM 2135, Leica Instruments, Nussloch, Germany). These sections were stained with hematoxylin–eosin and Masson's trichrome.

### Evaluation of histomorphology of arterial tissue

To investigate the images obtained from the sections, an image analysis method using a computer video camera were used (UTHSC Image software). All sections were analyzed, only sections with clear artifacts linked to staining were excluded from the evaluation. After staining was completed the sections were investigated under a light microscope (Olympus BX-51, Tokyo, Japan) and images were evaluated after uploading to a computer with a high resolution camera (Olympus DP-71, Japan). All sections were digitally photographed.

Under the light microscope arterial tissue sections of the subject group were evaluated for arterial endothelial regularity and integrity, and regularity of the internal elastic membrane and underlying smooth muscle and elastic fibers. The groups were scored semi quantitatively for endothelial damage, elastic membrane and elastic fiber damage, smooth muscle hypertrophy, and increase in connective tissue. The scoring was 0 = none, 1 = very slight damage, 2 = slight damage, 3 = moderate damage, and 4 = severe damage.<sup>8</sup>

### Statistical analysis

Statistical analysis was performed by using the Statistical Package for the Social Sciences (SPSS) version 16.0 for

Windows (SPSS Inc., Chicago, IL, USA). The Kolmogorov–Smirnov test was used to examine compatibility between measured variables and normal distribution. Mann–Whitney *U* test was used for statistical analysis. Descriptive statistics included arithmetic median (minimum–maximum). A *p*-value < 0.05 was considered significant.

### Results

The ear artery cross-sections of a total of 28 New Zealand type white rabbits were evaluated.

After rabbits were given the study medications intrarterially until the end of the 72 h evaluation period, macroscopic ischemia and necrosis findings were not observed in the ears of any rabbit given sugammadex and dexmedetomidine.

All rabbit's ears arterial tissues had investigated histologically.

It was observed that the arterial tissue of the control group had normal histological structure. The arterial endothelium was regular and there was no disruption of the endothelial continuity observed. The internal elastic membrane was regular and there was no irregularity observed in the organization of the underlying smooth muscle and elastic fibers (Figs. 1–3).

The catheter group samples had similar characteristics to the control group (Figs. 1–3).

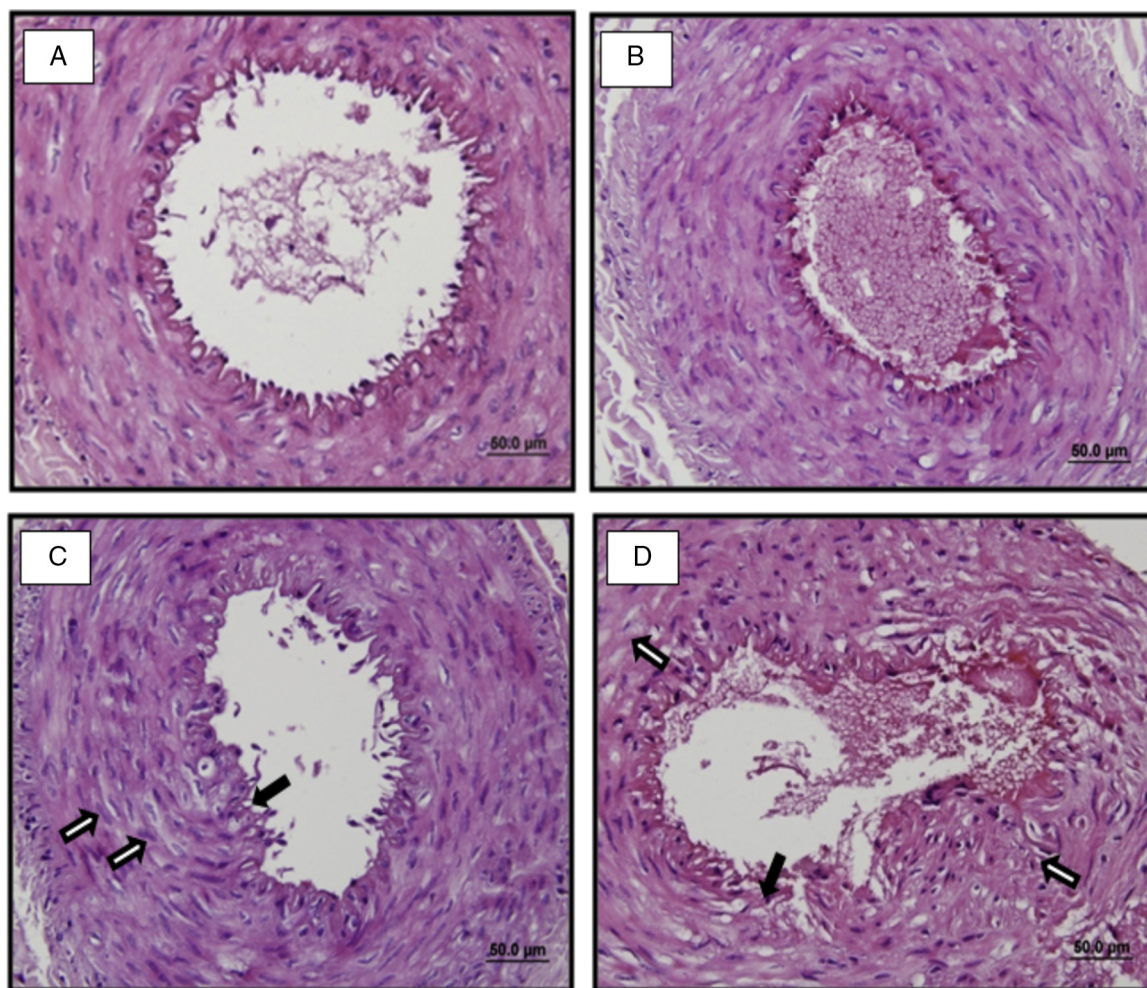
When the dexmedetomidine group was evaluated, compared to the control group there were clear areas of tissue damage observed in some subjects. Endothelial irregularity, disruption of the endothelial integrity and in place endothelial hypertrophy was observed. There was irregularity in the internal elastic membrane, and disorganization of the regularity of underlying smooth muscle and elastic fibers. In the tunica media there was smooth muscle hypertrophy identified. When this group is compared to the control group, there was an increase in connective tissue found (Figs. 1–3).

When the samples from the sugammadex group are evaluated and compared with the control group, irregularity in the endothelium and disruption of the integrity of the endothelium were observed. The sugammadex groups were observed to have better preservation of the arterial tissue compared to the dexmedetomidine group. Endothelial hypertrophy was not observed. The irregularity of the internal elastic membrane and disorganization of underlying smooth muscle and elastic fibers and increase in connective tissue were observed to be less compared with the dexmedetomidine group (Figs. 1–3).

When the results of the histological evaluation of the groups is investigated, there was no significant difference found between the control and catheter groups in terms of scores for endothelial damage, damage to elastic membrane and elastic fibers, smooth muscle hypertrophy and connective tissue increase ( $p > 0.05$ ).

The endothelial damage, elastic membrane and elastic fiber damage, smooth muscle hypertrophy and connective tissue increase scores in the dexmedetomidine and sugammadex groups were significantly higher than both the control group ( $p < 0.05$ ) and the catheter group ( $p < 0.05$ ).

There was no significant difference found between the dexmedetomidine and sugammadex groups in terms of



**Figure 1** Representative light-microscopic images of H-E staining in vascular tissue in the control group (A), catheter group (B), sugammadex group (C), and dexmedetomidine group (D). ( $\rightleftharpoons$ ) indicate smooth muscle hypertrophy and ( $\blacktriangleright$ ) indicate endothelial damage.

scores for endothelial damage, elastic membrane and elastic fiber damage, smooth muscle hypertrophy and connective tissue increase ( $p > 0.05$ ). The results of the histological evaluation of the groups can be seen in [Table 1](#).

## Discussion

This study aimed to research the histological effects of 4 mg/kg sugammadex and 1 µg/kg dexmedetomidine

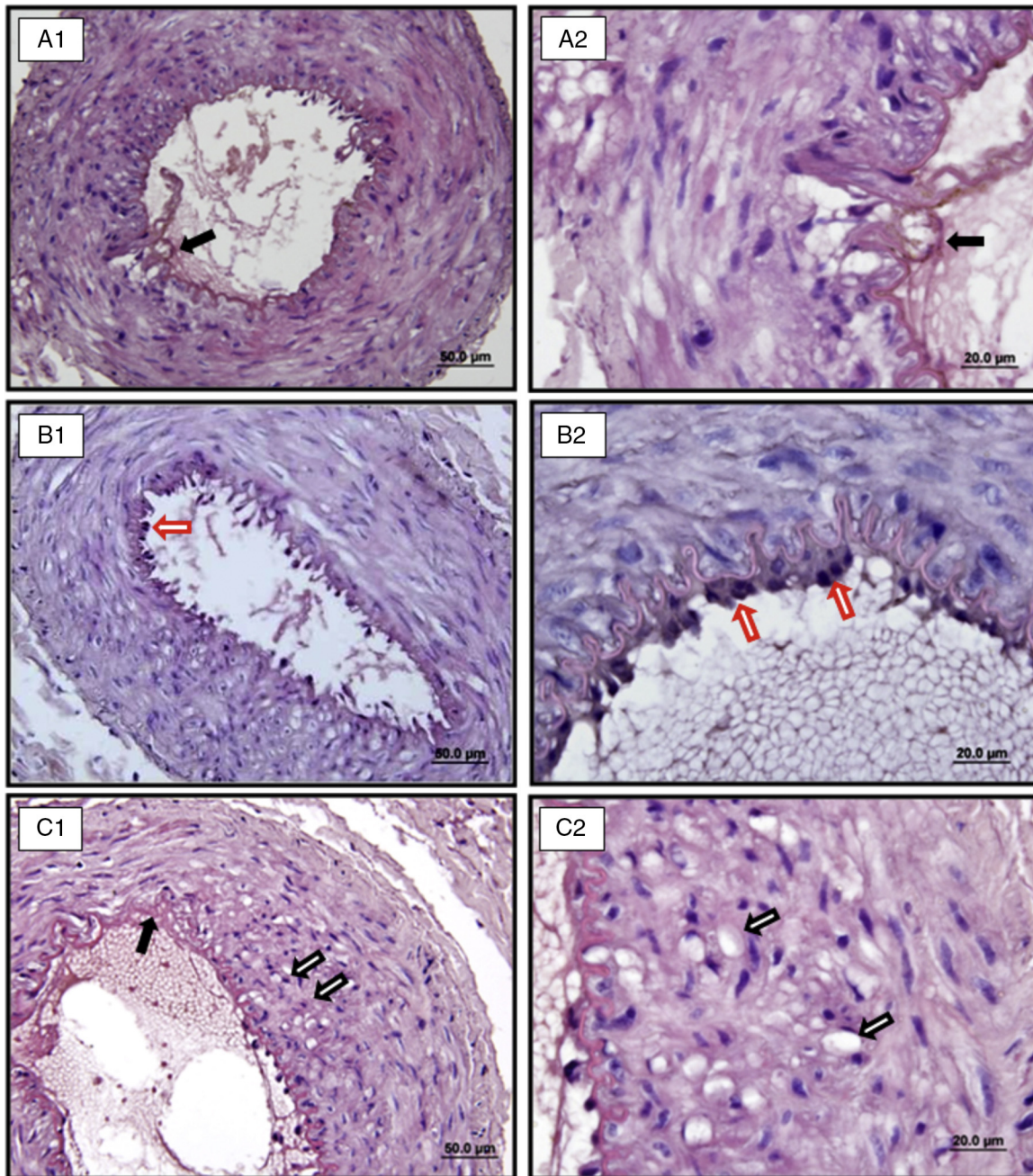
administered intra-arterially using rabbit ear arteries. After the administration of dexmedetomidine and sugammadex it was observed that scores for histological; endothelial damage, elastic membrane and elastic fiber damage, smooth muscle hypertrophy and increase in connective tissue were significantly higher compared with control and catheter groups. Additionally in no rabbit was tissue ischemia and tissue necrosis observed after intra-arterial administration of dexmedetomidine and sugammadex.

**Table 1** Histological evaluation of the study groups [median (minimum–maximum)].

Groups	Endothelial damage	Damage to elastic membrane and elastic fibers	Smooth muscle hypertrophy	Connective tissue increase
Group Control ( $n=7$ )	0.0 (0.0–0.0)	0.0 (0.0–1.0)	0.0 (0.0–1.0)	0.0 (0.0–0.0)
Group Catheter ( $n=7$ )	0.0 (0.0–1.0)	0.0 (0.0–1.0)	0.0 (0.0–0.0)	0.0 (0.0–1.0)
Group Dexmedetomidine ( $n=7$ )	2.0 (2.0–3.0) <sup>a,b</sup>	2.0 (2.0–3.0) <sup>a,b</sup>	2.0 (2.0–3.0) <sup>a,b</sup>	2.0 (1.0–3.0) <sup>a,b</sup>
Group Sugammadex ( $n=7$ )	2.0 (1.0–2.0) <sup>a,b</sup>	2.0 (1.0–2.0) <sup>a,b</sup>	2.0 (1.0–2.0) <sup>a,b</sup>	2.0 (1.0–2.0) <sup>a,b</sup>

<sup>a</sup>  $p < 0.05$ , in comparison with Group Control, Mann–Whitney  $U$  test.

<sup>b</sup>  $p < 0.05$ , in comparison with Group Catheter, Mann–Whitney  $U$  test.

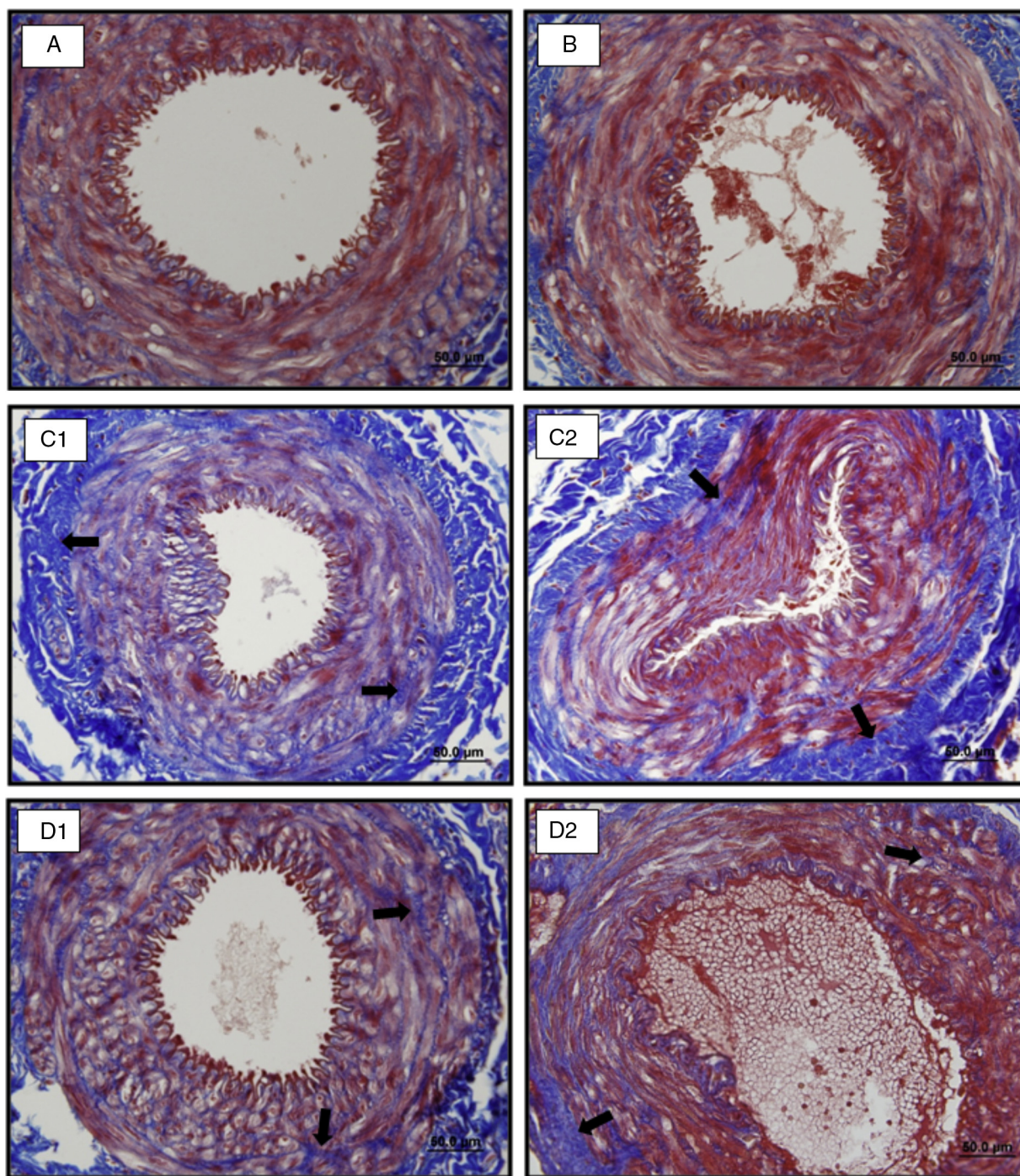


**Figure 2** Representative light-microscopic images of H-E staining (A1–B1–C1 40× and A2–B2–C2 100× magnification) in vascular tissue in the dexmedetomidine group. (⇔) indicate smooth muscle hypertrophy, (➤) indicate disorder in membrane elastica interna, and (⇨) indicate endothelial hypertrophy.

As a result of mistaken administration of medications intra-arterially, serious complications such as endothelial destruction, tissue necrosis, thrombosis and loss of extremities may occur.<sup>1,2,9,10</sup> The majority of cases of medication mistakenly administered intra-arterially involve agents used for anesthesia and sedation.<sup>1,2</sup> Various studies have reported the incidence of iatrogenic intra-arterial cannula insertion and intra-arterial medication administration as having rates between 1/56,000 and 1/3440.<sup>2,10</sup> Studies by D'Eramo et al.<sup>11</sup> reported this rate as 2/57,575. However it is difficult to determine the correct incidence of situations that are

rare, like this one.<sup>1,10</sup> When confronted with this unwanted situation though it is reported that early intervention is of great importance, there are no well-described treatment methods for patients.<sup>12,13</sup>

Following intra-arterial injection, discomfort, local irritation and intense pain distal from the injection site are observed as the first symptoms frequently within seconds. Pain may be described as similar to an electric shock or a burning sensation in the fingertips. A short time later, the patient may describe sensory problems like tingling, burning and numbness. Changes in motor functions like involuntary



**Figure 3** Representative light-microscopic images of Masson's trichrome staining in vascular tissue in the control group (A), catheter group (B), sugammadex group (C), and dexmedetomidine group (D) (►) indicate increase in connective tissue.

muscle spasms and muscle weakness and skin findings of redness and skin rashes may be encountered.<sup>1,2,10,14</sup>

Ghouri et al.<sup>10</sup> reported the signs that may cause intra-arterial cannulization to be considered as bright red blood coming from the cannula, pulsatile movement of the cannula, blood flows back into the serum set even though the junction of fluid and cannula is higher, cannulas in high risk areas where arteries and veins are close such as the ante-cubital region, and pressure increase in arterial catheter

previously inserted in the same extremity. However in our case of intra-arterial pheniramine injection, diagnosis was only possible after blood gas analysis, and if intra-arterial administration is suspected confirmation tests of blood gas analysis or intra vein pressure measurements should be performed.<sup>1</sup>

The most important stage of treatment for intra-arterial injection is to provide anticoagulation with heparin and local thrombolytics as quickly as possible to patients

without contraindications.<sup>15</sup> An important part of treatment is formed by preventing vasospasm in the artery. Intra-arterial administration of local anesthetics like procaine and lidocaine and vasodilators like papaverine are aimed at preventing vasospasm.<sup>1,2,10,15</sup> Peripheral nerve block administration is an interventional treatment method for intra-arterial injections aiming to reduce or prevent reflex vasospasm and lengthened vasoconstriction by providing sympathetic blockage. This intervention may reduce pain, provide perfusion and reduce vasospasm and efficiently achieves therapeutic aims. Continuous administration with the aid of a catheter increases the benefits of the technique. However peripheral nerve blocks may not be the first choice of intervention for some patients due to the associated risks.<sup>1,2,10,15</sup>

As case-controlled human studies of intra-arterial medication injections cannot be performed, there are very few publications about treatment presenting experimental studies and treatment algorithms.<sup>16–18</sup> Using the rabbit ear model is a good alternative to research the pathological process of intra-arterial injection. Knill and Evans<sup>4</sup> researched the intra-arterial effects of thiopental, chlorpromazine and amphetamine using the rabbit ear model and found that medication doses causing gangrene in humans had the same effect on rabbit ears. As a result we chose to use the rabbit ear model in this study.

Though the clinical tableau of intra-arterial injections is well described, the underlying physiopathological mechanisms are not clear. Studies have mentioned mechanisms such as norepinephrine-moderated vasoconstriction, creation of platelet aggregation and intra-arterial thrombus linked to medication or cannula, endothelial inflammation, direct cytotoxic effects, lipophilic characteristics of the medication and osmolarity characteristics of the medication.<sup>1,2,10,15</sup> The common result of these studies is that all medications do not cause ischemia by the same pathway, that the last common point in the pathogenesis of all intra-arterial injections independent of the variety of mechanisms is thrombosis and as it is not suitable for broad prospective human studies, clear understanding of the pathogenesis is necessary for development of correct treatment models.<sup>1,2,10,15</sup>

In the literature there are many cases reported of serious complications observed after intra-arterial medication injection. It is reported that as a result of iatrogenic administration of local anesthetic agent through intra-arterial routes, rhabdomyolysis occurred.<sup>19</sup> In the benzodiazepin group, after diazepam and temazepam, fasciotomy and amputation were performed due to the occurrence of phlebitis, vascular disorders, and arterial and venous thrombosis.<sup>20–23</sup> After phenytoin was given by arterial route ischemia, necrosis and death was reported,<sup>24</sup> while after promazine, promethazine and chlorpromazine from the phenothiazine group necrosis and extremity loss have been reported.<sup>25,26</sup> After thiopental, a barbiturate, endoarteritis, vasoconstriction, thrombosis and tissue necrosis occurred.<sup>27–30</sup> Similar results were encountered as a result of antibiotics given by arterial route. There are cases of necrosis and tissue loss found with penicillin, floxacillin and clindamycin, frequently used in daily practice.<sup>31–33</sup> Clear ischemic appearance and gangrene have been reported after intra-arterial administration of atracurium

and tubocurarine, used in anesthesia as neuromuscular blockers.<sup>34,35</sup>

In addition to these catastrophic results, more moderate progression after intra-arterial administrations is found. Different results are reported for different paracetamol preparations. A 7 year old case undergoing craniotomy for medulloblastoma was given 350 mg paracetamol into the radial artery by mistake during the postoperative period. The case was monitored but asymptomatic and on the 7th day postoperative doppler ultrasonography revealed radial artery pulsation was normal. However a 42 year old case undergoing laparoscopic cholecystectomy was mistakenly given 900 mg benzyl alcohol-based paracetamol intra-arterially at the end of surgery for postoperative analgesia. When the patient complained in the recovery unit of pain in the right hand, this pain was thought to be possibly due to mistaken injection in the cannula inserted in the right radial artery. Forty minutes later as a result of noticing blue color changes in 2 fingers responding to radial artery distribution, treatment was begun; however in spite of this the affected fingers had to be amputated. As a result the authors stated that medications prepared with preservatives like water-insoluble benzyl alcohol may lead to endothelial edema and capillary endothelial dysfunction causing vasospasm.<sup>36</sup>

Intra-arterial complications of water-insoluble medications like propofol, etomidate and diazepam,<sup>24,35–37</sup> and high alkali medications like thiopental and phenytoin<sup>24,27</sup> have been known for years. Contrary to this there are no unwanted effects of intra-arterial injection of medications like atropine, succinylcholine, pancuronium, midazolam and fentanyl.<sup>24</sup> The side effects of medication like adenosine, neostigmine–atropine combination and neostigmine–glycopyrrolate have not been reported.<sup>38,39</sup> It is known that more complications are caused by membrane-soluble medications.<sup>4</sup>

Babacan et al.<sup>30</sup> in a study researching the histopathological criteria of intra-arterial effects of thiopental and propofol in rabbits found that intra-arterial administration of 2.5% thiopental may be responsible for gangrenous changes and though this effect was not found with 1% propofol, they concluded it could cause clear edema.

Though there is much literature information on the intra-arterial effects of many agents used in anesthesia, the studies on sugammadex and dexmedetomidine which have newly entered clinical application are very limited.

Sugammadex is a modified gamma cyclodextrin molecule which has newly entered trade use. The unique molecular structure of sugammadex encapsulates rocuronium, a neuromuscular blocker, removing it from the muscle–nerve junction and it is used to selectively and rapidly reverse neuromuscular blockage. Cyclodextrins are empty cut-off cone-shaped or ring-shaped “donut-like” molecules with hydrophobic cavity and hydrophilic outer structure containing sugar rings (D-glucopyranose units) in a 3-dimensional structure, frequently used in food and pharmaceutical industries to transform lipophobic agents into lipophilic types. The negatively charged hydroxyl groups make the molecule soluble in water. The carbon atoms together with the contained alpha 1–4 links provide the lipophilic

cavity. Thus the water-soluble molecule surrounds a lipophilic core. This structure is of a suitable size to encapsulate lipophilic medications and increase water solubility. Non-covalent thermodynamic interactions can form inclusion complexes. The cavity size is larger than alpha and beta gamma cyclodextrin and is 0.8 nm. Thermodynamic, Van der Waals, hydrophobic interactions, hydrogen and charge transfer interactions contribute to the formation of inclusion complexes (host-guest complexes). The inclusion complex is an encapsulated lipophilic molecule. The sugammadex vial contains injection water prepared with hydrochloric acid and sodium hydroxide to adjust pH.<sup>5,40</sup>

In our literature analysis we did not encounter any clinical or experimental data related to the intra-arterial effects of sugammadex. In our study, after 4 mg/kg intra-arterial sugammadex administration, histological endothelial damage, elastic membrane and elastic fiber damage, smooth muscle hypertrophy were observed. In addition, connective tissue scores were significantly higher compared to the control and catheter groups.

A selective  $\alpha$ -2 adrenoreceptor agonist, dexmedetomidine has gained a place in anesthesia practice due to its sedative and analgesic effects. Though dexmedetomidine has sedative, analgesic, and anxiolytic effects, it does not cause respiratory depression. When given as continuous IV infusion it provides predictable stable hemodynamics. Dexmedetomidine is widely used across a variable spectrum from neuroanesthesia, the intensive care patient population, gastrointestinal endoscopy, and conscious fiberoptic intubation.<sup>41,42</sup> We found one case study of intra-arterial administration of dexmedetomidine in the literature. This case study emphasized that after dexmedetomidine was mistakenly administered to the radial artery no ischemic complications were encountered.<sup>6</sup> In our study though tissue ischemia and tissue necrosis were not observed after intra-arterial administration of 1  $\mu$ g/kg dexmedetomidine as infusion over 10 min using rabbit ear arteries, histological evaluation observed endothelial damage, elastic membrane and elastic fiber damage, smooth muscle hypertrophy and connective tissue increase scores were significantly higher than in the control and catheter groups.

The most important limitation of our study is that we only used a single dose of sugammadex and dexmedetomidine. Our study was only able to obtain ethics committee permission for single doses (4 mg/kg sugammadex and 1  $\mu$ g/kg dexmedetomidine). To research whether sugammadex and dexmedetomidine cause vein damage related to dose, advanced studies with different doses are required.

In conclusion, administration of sugammadex and dexmedetomidine, newly entered anesthesia practice and with increasing popularity, to rabbits by intra-arterial routes caused histological arterial damage. To understand the histological changes caused by sugammadex and dexmedetomidine more clearly, more experimental research is needed.

## Conflicts of interest

The authors declare no conflicts of interest.

## References

- Hancı V, Yurtlu SB, Bilir S, Ayoğlu H, Demircan N, Turan İÖ. Successful treatment for intra-arterial injection of pheniramine: case report. *J Anesth Reanim.* 2009;7:40–3.
- Sen S, Çınır EN, Brown JM. Complications after unintentional intra-arterial injection of drugs: risks, outcomes and management strategies. *Mayo Clin Proc.* 2005;80:783–95.
- Lake C, Beecroft CL. Extravasation injuries and accidental intra-arterial injection. *Crit Care Pain.* 2010;10:109–13.
- Knill RL, Evans D. Pathogenesis of gangrene following intra-arterial injection of drugs: a new hypothesis. *Can Anaesth Soc J.* 1975;22:637–46.
- Hancı V, Ali Kiraz H, Ömür D, Ekin S, Uyan B, Yurtlu BS. Precipitation in Gallipoli: sugammadex/amiodarone & sugammadex/dobutamine & sugammadex/protamine. *Rev Bras Anesthesiol.* 2013;63:163–4.
- Ghatak T, Samanta S. Accidental intra-arterial dexmedetomidine injection in postoperative ward. *Anaesth Intensive Care.* 2013;41:431.
- Kinmonth JB, Sheppard RC. Accidental injection of thiopentone into arteries: studies of pathology and treatment. *Br Med J.* 1959;2:914–9.
- Schwartz RS, Huber KC, Murphy JG, Edwards WD, Camrud AR, Vlietstra RE, et al. Restenosis and the proportional neointimal response to coronary artery injury: results in a porcine model. *J Am Coll Cardiol.* 1992;19:267–74.
- Mirzatołooei F, Afshar A. Intravenous injection of diazepam to cubital vein can be complicated by accidental intra-arterial penetration and gangrene. *Arch Iran Med.* 2008;11:469–71.
- Ghouri AF, Mading W, Prabaker K. Accidental intraarterial drug injections via intravascular catheters placed on the dorsum of the hand. *Anesth Analg.* 2002;95:487–9.
- D'Eramo EM, Bookless SJ, Howard JB. Adverse events with outpatient anesthesia in Massachusetts. *J Oral Maxillofac Surg.* 2003;61:793.
- Topazian RG. Accidental intra-arterial injection: a hazard of intravenous medication. *J Am Dent Assoc.* 1970;81:410.
- Keene JR, Buckley KM, Small S, Geldzahler G. Accidental intra-arterial injection: a case report, new treatment modalities, and a review of the literature. *J Oral Maxillofac Surg.* 2006;64:965–8.
- Gori F, Moretti I, Mosca S, Pasqualucci A. Intra-arterial diazepam. Treatment and evaluation of a case. *Minerva Anesthesiol.* 1991;57:445.
- Righini M, Angellillo-Scherrer A, Gueddi S, Le-Gal G, Bounameaux H. Management of severe ischemia of the hand following intraarterial injection. *Thromb Haemost.* 2005;94:219–21.
- Seak CK, Kooi XJ, Seak CJ. Acute hand ischemia after intra-arterial injection of meprobamate powder. *J Emerg Med.* 2012;43:468–71.
- Zachary LS, Smith DJ, Hegggers JP, Robson MC, Boertman JA, Niu XT, Schileru RE, Sacks RJ. The role of thromboxane in experimental inadvertent intra-arterial drug injections. *J Hand Surg.* 1987;12A:240–5.
- Buckspan GS, Franklin JD, Novak GR, Bennett BD, Lynch JB, Dean RH. Intraarterial drug injury: studies of etiology and potential treatment. *J Surg Res.* 1978;24:294–301.
- Selimoglu O, Basaran M, Ugurlucan M, Ogus TN. Rhabdomyolysis following accidental intra-arterial injection of local anesthetic. *Angiology.* 2009;60:120–1.
- Gould JD, Lingam S. Hazards of intra-arterial diazepam. *BMJ.* 1977;2:298–9.
- Schneider S, Mace JW. Loss of limb following intravenous diazepam. *Pediatrics.* 1974;53:112–4.



22. Schulenburg CE, Robbs JV, Rubin J. Intra-arterial diazepam: a report of 2 cases. *S Afr Med J*. 1985;68:891–2.
23. Sivalingam P. Inadvertent cannulation of an aberrant radial artery and intra-arterial injection of midazolam [letter]. *Anaesth Intensive Care*. 1999;27:424–5.
24. Fikkers BG, Wuis EW, Wijnen MH, Scheffer GJ. Intraarterial injection of anesthetic drugs. *Anesth Analg*. 2006;103:792–4.
25. Hager DL, Wilson JN. Gangrene of the hand following intra-arterial injection. *Arch Surg*. 1967;94:86–9.
26. Hodges RJ. Gangrene of forearm after intra-muscular chlorpromazine. *BMJ*. 1959;2:918–9.
27. MacPherson RD, McLeod LJ, Grove AJ. Intra-arterial thiopentone is directly toxic to vascular endothelium. *Br J Anaesth*. 1991;67:546–52.
28. Angel MF, Amiss EC, Amiss LR, Morgan RF. Deleterious effect of urokinase used to treat experimental intra-arterial thiopental injection injuries. *Ann Plast Surg*. 1992;28:281–3.
29. Vangerven M, Delrue G, Brugman E, Cosaert P. A new therapeutic approach to accidental intra-arterial injection of thiopentone. *Br J Anaesth*. 1989;62:98–100.
30. Babacan A, Akçabay M, Uluoğlu O, Ozkoçak I, Karadenizli Y. The histopathological comparison of the results of the intra-arterial injections of propofol and thiopentone in rabbits. *Mater Med Pol*. 1992;24:41–4.
31. Ozel A, Yavuz H, Erkul I. Gangrene after penicillin injection (a case report). *Türk J Pediatr*. 1995;37:67–71.
32. Aghoutane EM, Fezzazi R, Elhaouati R, Boumzebra D. Fingers necrosis after an accidental intra-arterial injection of flucloxacilline: case report. *Chir Main*. 2011;30:120–2.
33. Lehavi A, Sandler A, Netzer A, Katz Shai Y. Vascular injury following accidental intra-arterial injection of clindamycin: adverse drug reaction report. *Minerva Anesthesiol*. 2011;77:468–9.
34. Fell JN. Intra-arterial injection of tubocurarine and thiopental. *BMJ*. 1953;1:95–6.
35. Kessell G, Barker I. Leg ischaemia in an infant following accidental intra arterial administration of atracurium treated with caudal anaesthesia. *Anaesthesia*. 1996;51:1154–6; MacPherson RD, Rasiah RL, McLeod LJ. Intraarterial propofol is not directly toxic to vascular endothelium. *Anesthesiology*. 1992;76:967–71.
36. Samanta S, Chakraborty N, Samanta S. Accidental intra-arterial injection of paracetamol. Different preparations, different results. *Eur J Anaesthesiol*. 2013;30:1–2; Brimacombe J, Gandini D, Bashford L. Transient decrease in arm blood flow following accidental intra-arterial injection of propofol into the left brachial artery. *Anaesth Intensive Care*. 1994;22:291–2.
37. Ohana E, Sheiner E, Gurman GM. Accidental intra-arterial injection of propofol. *Eur J Anaesthesiol*. 1999;16:569–70.
38. ter Schure JM, de Vries TW. Accidental intra-arterial injection of adenosine in a patient with supraventricular tachycardia. *Cardiol Young*. 2011;21:601.
39. Jain A, Sahni N, Banik S, Solanki SL. Accidental intraarterial injection of neostigmine with glycopyrrolate or atropine for reversal of residual neuromuscular blockade: a report of two cases. *Anesth Analg*. 2012;115:210–1.
40. Hancı V, Ozbilgin S, Boztaş N, Yurtlu DA, Onat L, Kamacı G, Yurtlu BS, Guneli ME, Şişman AR, Arıkanoğlu A. Evaluation of the effectiveness of sugammadex for teophylline/aminophylline intoxication: an experimental study. *Lat Am J Pharm*. 2014;33:1290–6.
41. Hancı V, Yurdakan G, Yurtlu S, Turan İÖ, Sipahi EY. Protective effect of dexmedetomidine in a rat model of  $\alpha$ -naphthylthiourea-induced acute lung injury. *J Surg Res*. 2012;178:424–30.
42. Hancı V, Erdoğan G, Okyay RD, Yurtlu BS, Ayoğlu H, Baydilek Y, Turan İO. Effects of fentanyl–lidocaine–propofol and dexmedetomidine–lidocaine–propofol on tracheal intubation without use of muscle relaxants. *Kaohsiung J Med Sci*. 2010;26:244–50.