



# REVISTA BRASILEIRA DE ANESTESIOLOGIA

Publicação Oficial da Sociedade Brasileira de Anestesiologia  
www.sba.com.br



## SCIENTIFIC ARTICLE

# Comparative immunohistochemical assessment of the effect of repetitive anesthesia with isoflurane and sevoflurane on rat liver<sup>☆</sup>



Flavia Ruxanda<sup>a</sup>, Adrian Florin Gal<sup>b,\*</sup>, Cristian Rațiu<sup>c</sup>, Viorel Miclăuș<sup>a</sup>, Vasile Rus<sup>a</sup>, Liviu Ioan Oana<sup>d</sup>

<sup>a</sup> Department of Cell Biology, Histology and Embriology, University of Agricultural Sciences and Veterinary Medicine, Cluj-Napoca, Romania

<sup>b</sup> Department of Pathological Anatomy, University of Agricultural Sciences and Veterinary Medicine, Cluj-Napoca, Romania

<sup>c</sup> Department of Implantology, Faculty of Medicine and Pharmacy, University of Oradea, Oradea, Romania

<sup>d</sup> Department of Anesthesiology and Surgical Propedeutics, University of Agricultural Sciences and Veterinary Medicine, Cluj-Napoca, Romania

Received 14 January 2015; accepted 11 February 2015

Available online 26 September 2015

### KEYWORDS

Anesthesia;  
Caspase-3;  
Isoflurane;  
Liver;  
Sevoflurane

### Abstract

**Background and objectives:** Inhalation anesthetics are used in human, as well as veterinary medical practice. In the present study we investigated the effect of isoflurane and sevoflurane on rat hepatocytes.

**Methods:** A total of 40 Wistar female rats were used in this study. Animals were divided in groups of 5 rats. Groups IM, SM served as control groups. Groups I1, I2, I3 were used to study isoflurane and S1, S2, S3 for sevoflurane study. They were anesthetized 3 times, for 2 h long, at 2 days interval with a concentration of: 1.5% isoflurane (I1, I2, I3) and 2% sevoflurane (S1, S2, S3). The oxygen supply throughout the anesthesia was 1 L O<sub>2</sub>/min. Groups IM, IS, I1, S1 were sacrificed immediately after the last anesthesia. Groups I2, S2 were sacrificed 6 h after the last anesthesia, and groups I3, S3, 24 h post-anesthesia. Liver samples were harvested to highlight caspase-3 in apoptotic hepatocytes.

**Results:** Following isoflurane administration, there were less than 1% cells in apoptosis highlighted in rat livers from groups IM, I1 and I2. At 24 h post-anesthesia (group I3), a small number of apoptotic hepatocytes was highlighted (around 3.23% cells in apoptosis), with a strictly periacinar disposition, randomly distributed in a small number of hepatic lobules. After sevoflurane administration, less than 1% apoptotic hepatocytes were identified at all control moments throughout the study.

<sup>☆</sup> The study was carried out at the Department of Anesthesiology and Surgical Propedeutics, University of Agricultural Sciences and Veterinary Medicine, Cluj-Napoca, Romania.

\* Corresponding author.

E-mail: [adrianfloringal@yahoo.com](mailto:adrianfloringal@yahoo.com) (A.F. Gal).

**PALAVRAS-CHAVE**

Anestesia;  
Caspase-3;  
Isoflurano;  
Fígado;  
Sevoflurano

**Conclusions:** The results suggest that the anesthetics do not present a considerable hepatotoxicity. The comparative assessment of the two anesthetics shows that sevoflurane is superior to isoflurane.

© 2015 Sociedade Brasileira de Anestesiologia. Published by Elsevier Editora Ltda. This is an open access article under the CC BY-NC-ND license (<http://creativecommons.org/licenses/by-nc-nd/4.0/>).

### Avaliação imuno-histoquímica comparativa do efeito da anestesia repetitiva com isoflurano e sevoflurano sobre o fígado de rato

**Resumo**

**Justificativa e objetivos:** Anestésicos inalatórios são usados em humanos e também na prática médica veterinária. No presente estudo investigamos o efeito de isoflurano e sevoflurano em hepatócitos de rato.

**Métodos:** No total, 40 ratos Wistar fêmeas foram usados neste estudo. Os animais foram divididos em grupos de cinco ratos cada. Os grupos IM e SM serviram como grupos controle. Os grupos I1, I2 e I3 foram usados para o estudo de isoflurano e os grupos S1, S2 e S3 para o estudo de sevoflurano. Os ratos foram anestesiados três vezes, durante o período de 2 horas em intervalos de dois dias, com uma concentração de 1,5% de isoflurano (I1, I2, I3) e 2% de sevoflurano (S1, S2, S3). O fornecimento de oxigênio durante a anestesia foi de 1 L O<sub>2</sub>/min. Os grupos IM, IS, I1 e S1 foram sacrificados imediatamente após a última anestesia. Os grupos I2 e S2 foram sacrificados 6 horas após a última anestesia e os grupos I3 e S3 foram sacrificados 24 horas após a anestesia. Amostras dos fígados foram colhidas para ressaltar a caspase-3 em hepatócitos apoptóticos.

**Resultados:** Após a administração de isoflurano, havia menos de 1% das células em apoptose em destaque nos fígados dos ratos dos grupos IM, I1 e I2. Às 24 horas após a anestesia (grupo I3), um pequeno número de hepatócitos apoptóticos foi destacado (cerca de 3,23% de células em apoptose), com uma disposição estritamente periacinar, distribuídos aleatoriamente em um pequeno número de lóbulos hepáticos. Após a administração do sevoflurano, menos de 1% de hepatócitos apoptóticos foi identificado em todos os momentos de controle ao longo do estudo.

**Conclusões:** Os resultados sugerem que os anestésicos não apresentam uma hepatotoxicidade considerável. A avaliação comparativa dos dois anestésicos mostra que sevoflurano é superior ao isoflurano.

© 2015 Sociedade Brasileira de Anestesiologia. Publicado por Elsevier Editora Ltda. Este é um artigo Open Access sob uma licença CC BY-NC-ND (<http://creativecommons.org/licenses/by-nc-nd/4.0/>).

**Introduction**

Inhalational anesthetics are widely used in both human and veterinary medicine. They can be utilized in anesthetic management in a large number of species, including reptiles, birds and wild animals.<sup>1-5</sup> The primary site for metabolism of inhalational anesthetics is represented by the liver.<sup>6,7</sup> Under these circumstances, it is possible that some physiological or morphological changes appear in the liver, due to either the direct action of these anesthetics or some intermediary metabolites resulted during their degradation. These aspects have made the object of numerous studies which brought much useful information, but there are still controversies surrounding the inhalational anesthetics' action on the liver. Thus, there are studies that report a minor liver enzymes elevation, while others report fulminant necrotic hepatitis, resulting even in patient's death.<sup>8-10</sup>

The great majority of the investigations have studied the inhalational anesthetic effects on liver function.<sup>11</sup> Macro and especially microscopic aspects were the object of study of

a relatively small number of investigations. Some authors sustain that prolonged anesthesia with isoflurane does not induce hepatic lesions in animals.<sup>12-14</sup> Soubhia et al.<sup>10</sup> evaluated the transaminase activity, and also the liver, histologically, after exposure to sevoflurane, recording slightly increased values for transaminase activity and no morphological change of the liver parenchyma in light microscopy. Honda et al.<sup>15</sup> evaluated both liver function and morphology after exposure to isoflurane and sevoflurane. The conclusion of the study was that the degree of hepatic lesions induced by isoflurane exposure was higher than the one induced by sevoflurane. Elena et al.<sup>16</sup> studied liver, kidney and spleen physiology and histology after repeated sevoflurane anesthesia. The authors did not detect an altered liver and renal function or changes in the architecture of these organs. Other authors report histopathological lesions varying from panlobular, to multifocal, even fulminant necrosis.<sup>17</sup> A case of fulminant liver failure was reported after the third exposure to isoflurane, with submassive and massive necrosis at histopathological examination.<sup>8</sup> Zizek et al.<sup>9</sup> also report

fatal subacute liver failure, with massive necrosis of hepatocytes, at repeated sevoflurane anesthesia.

Considering the small number of morphological investigations and especially the conflicting available information in the specialty literature, we considered opportune to conduct histological and immunohistochemical investigations regarding the isoflurane and sevoflurane effect on rat liver.

## Methods

The experimental protocol was approved by the Scientific Research Ethics Committee of UASVM (University of Agricultural Sciences and Veterinary Medicine) Cluj-Napoca and was conducted in accordance with the Ministry of Health force and with the pertained European legislation. The experimental study was conducted in the Biobase of UASVM Cluj-Napoca and in the Department of Anesthesiology and Surgical Propedeutics, UASVM Cluj-Napoca.

A total of 40 6 week-old Wistar female rats were used in the experimental study. The rats were randomly divided in 8 groups, 5 rats each. Two of them served as control groups: IM (control isoflurane) and SM (control sevoflurane), rats in this group being exposed to oxygen alone (1 L/min) 3 times, for 2 h long, at 2 days interval. Three groups (I1, I2 and I3) were subjected to isoflurane anesthesia at a concentration of 1.5% and the other three (S1, S2 and S3) to sevoflurane at a 2% concentration. At the utilized concentrations, the minimum alveolar concentration (MAC) was approximately 1 in the case of isoflurane,<sup>18</sup> as well as sevoflurane.<sup>19</sup> The concentration of anesthetic was adjusted by using a vaporizer.

We used an induction box for anesthetics. The rats were introduced in the induction box 15 min before initiating the anesthesia, in order to accommodate. Experimental groups were anesthetised 3 times, for 2 h long, at 2 days interval. The oxygen supply throughout the anesthesia was 1 L O<sub>2</sub>/min for both isoflurane and sevoflurane. We followed the protocol recommended by Honda et al.,<sup>15</sup> mentioning that the anesthetics were repeated 3 times in order to see the effects of repeated anesthesia with isoflurane and sevoflurane.

After completing the anesthetics, the rats were sacrificed through cervical dislocation, at different post-anesthetic times: groups IM, SM, I1 and S2 immediately after the anesthesia, groups I2, S2 – 6 h post-anesthesia and I3, S3 groups – 24 h post-anesthesia.

Immediately after the euthanasia, liver samples were harvested, introduced in 10% buffered formalin for fixation. After the fixation period, the samples were embedded in paraffin and then sectioned at a 5 μm thickness and mounted on poly-L-lysine coated microscopic slides (for the immunohistochemical reaction).

In order to detect the apoptotic hepatocytes, we used the immunohistochemical reaction to highlight the caspase-3 expression, as marker of programmed cell death. With this purpose in view, Leica Bond-max™ Immunohistochemistry system (Leica Biosystems Melbourne, Bond Max model, M2 12154 series) was used. The immunomarcation was made with Rabbit Anti-Caspase-3 Polyclonal Antibodies (dilution 1/75, rabbit anti-caspase 3 polyclonal, Linaris, Biologische Produkte, Dossenheim, Germany – cat. n° RB-1197-R7). The steps taken by the system in order to stain the sections

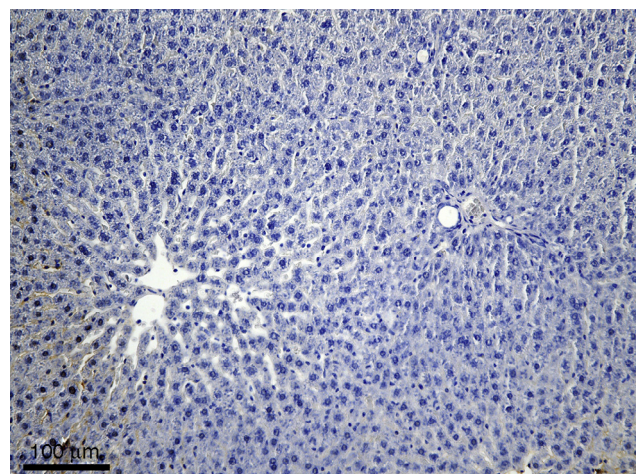
were the following: (a) deparaffinization and rinsing with an EDTA solution at 8.8 pH (Epitope Retrieval Solution 2), 98 °C for 20 min; (b) after rinsing, the DC 9800 kit was used for 10 min (Leica Microsystem GmbH) in order to block the endogenous peroxidase; (c) rinsing, after which the "rabbit anti-caspase-3" primary antibody was added and incubation for 30 min; (d) polymerase adding and incubation for 10 min, obtaining the color reaction with the help of DAB (diaminobenzidine).

Evaluation of the marker was made through quantification of immunomarked cells. Cells with a different intensity brown cytoplasm were considered positive. Immunomarked cells from 5 microscopic fields, at 400× magnification, were counted. The following grading method was used for each case: (I) less than 1% cells in apoptosis, (II) 1–2% cells in apoptosis, and (III) more than 2% cells in apoptosis. The microscopic images were obtained using the Olympus BX51 light microscope connected to an Olympus DP-25 digital photcamera, images being stored on a digital memory card and shown on the monitor.

## Results

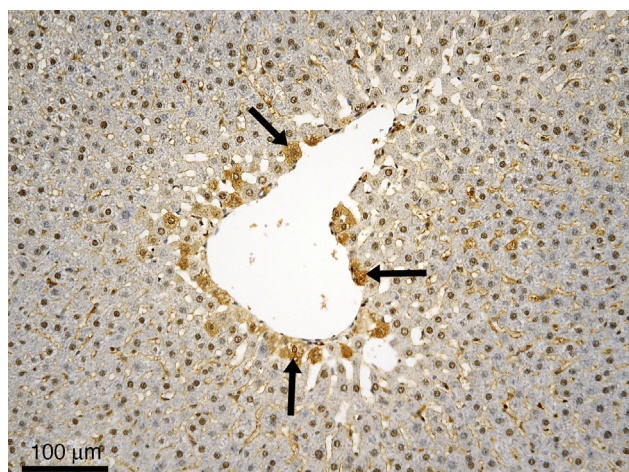
Immunohistochemical reaction for caspase-3 highlighted a small number of caspase-3 positive cells in rat livers from groups IM and SM (i.e., less than 1% cells in apoptosis), no more that the normal hepatocyte exchange rate. Apart from the fact they were scarce, the caspase-3 positive cells were isolated and scattered throughout the hepatic lobules. On most of the section area, the hepatic lobules had a normal structure and did not contain apoptotic cells (Fig. 1).

Livers from rats in I1 group did not present more caspase-3 positive cells than the control group (i.e., less than 1% cells in apoptosis), so that in the great majority of the lobules they were not present, not even isolated. The situation maintains in I2 group, regarding both the general aspect of the organ and the small number of apoptotic cells, comparable to the control group (i.e., less than 1% cells in apoptosis). First noticeable changes appear only in group I3 and consist of the presence of caspase-3 positive cells in some lobules



**Figure 1** Control group – no apoptotic cells; immunohistochemical reaction anti-caspase-3 polyclonal antibodies, Mayer hematoxylin counterstain.





**Figure 2** Experimental group I3 – centrilobular distributed apoptotic cells (suggested by a darker cytoplasm) – black arrows; immunohistochemical reaction anti-caspase-3 polyclonal antibodies, Mayer hematoxylin counterstain.

(around 3.23% cells in apoptosis, which represent more than 2% cells in apoptosis according to the suggested grading method). Some of the cells in the close vicinity of the centrilobular vein appear affected (Fig. 2). We mention that the phenomenon is not present in all of the hepatic lobules, but only in some of them. There were no inflammatory changes or circulatory disorders observed after exposure of the rats to isoflurane.

In the livers harvested from rats in group S1, the situation is comparable to the one in the control group, the number of caspase-3 positive cells being very small. A major increase of the caspase-3 positive cells is noticed in neither S2, nor S3 groups. No other associated lesions were observed (e.g., dystrophic, inflammatory lesions or circulatory disorders) in the liver after exposure of the subjects to sevoflurane.

## Discussion

Livers from rats in the control groups presented a normal aspect regarding the lobulation and the lobular pattern. Caspase-3 positive cells (i.e., in apoptosis) were identified, but their number was small, actually representing the normal hepatocyte exchange rate (aspect suggested by the isolated disposition, scattered throughout the hepatic lobules, with numerous hepatic lobules without immunomarked cells).

Livers from rats in group I1 were comparable to the ones from rats in the control group, from all points of view. Caspase-3 positive cells were present in small numbers and only in some lobules, so that we cannot state that after the anesthetic administration there were immediate adverse reactions, not even discrete ones. In group I2, no changes were observed regarding the apoptoses' distribution in liver in comparison to the two groups presented anteriorly. In group I3 a slight increase of the number of caspase-3 positive cells was observed, in comparison to the control, I1 and I2 groups. Comparative to the things observed in group IM, I1 and I2, in the case of subjects from group I3 a larger number of immunomarked cells (in apoptosis) was identified, focally

disposed, prevalingly centrilobular. A possible explanation of the affectation of the cells in the immediate vicinity of the centrilobular vein could be the fact that the anesthetic reaches the liver through the circulatory system, but in this situation, hepatocytes at the periphery of the lobules should be the first cells to give in, because that is the place that the sinusoids enter the hepatic lobules. But hepatocytes at the periphery of the lobules are favored in terms of nutrient and oxygen supplies, being the first to benefit due to their disposal, which seems to confer resistance to the anesthetic action. Cells in the vicinity of the centrilobular vein are the last to supply. Apparently, this makes them somewhat vulnerable, some of them entering apoptosis under anesthetic action. Other reports suggest that the periarterial zone is particularly vulnerable to apoptosis/necrosis (known as zone 3 or periarterial apoptosis/necrosis), partly because they are farthest from incoming arterial and portal venous blood, bearing oxygen and essential nutrients.<sup>20,21</sup>

However, the number of apoptotic cells is so small; we can state that isoflurane is an anesthetic with a good tolerance. The adverse reactions appeared in the liver after its administration in therapeutic dose is minimal, without other cellular lesions (e.g., dystrophies, necroses, vascular disorders) that induce changes in the pattern of the organ.

Sevoflurane administration did not result in the increasing of caspase-3 positive hepatocyte number in experimental groups immediately after the anesthesia or the other control times (6h and 24h post-anesthesia). At none of these moments, the caspase-3 positive cells were at such a level which would suggest that the anesthetic would trigger hepatocyte apoptosis. Apoptoses were present in a small number of cells, somehow comparable in all groups, which makes us state that their presence is absolutely normal, being linked to the normal hepatocyte exchange rate. In other terms, sevoflurane does not seem to have adverse reactions on rat liver, detectable through histological examination. This demonstrates a very good tolerability of sevoflurane in the liver.

The comparative assessment of the effect of the two anesthetics on rat liver highlights the fact that although both are well tolerated, at least at the dose and duration of administration chosen by us in this experimental protocol, there are certain differences between them. These differences refer to the fact that although isoflurane presents a good tolerance, it triggered apoptosis in a relatively small number of hepatocytes, whereas sevoflurane did not. Although the differences are minimal, the fact that sevoflurane presents a superior tolerability in comparison to isoflurane stands out. In this regard, our results are consistent with the reports of Nishiyama et al.,<sup>22</sup> Nishiyama<sup>23</sup> who state that the degree of the hepatic lesions induced by isoflurane exposure was greater than the one induced by sevoflurane. Honda et al.<sup>15</sup> make comparable statements, but the authors mentioned above were referring to other types of hepatic lesions, not apoptosis. Moreover, they state that they did not observe apoptosis from 0h to day 7 after exposure to isoflurane or sevoflurane, by using rabbit anti-ssDNA polyclonal antibodies. The explanation given by them is the fact that the results seem to have been influenced by the dose, which, according to them, might have been too large to allow apoptosis. The statement seems correct,

knowing that necrosis appears when the hypoxia is severe, while apoptosis takes place when the hypoxia is mild.<sup>24</sup>

The exact path of apoptosis induction by inhalational anesthetics is not entirely known, but there are studies which propose different hypotheses. Thus, Zhang et al.<sup>25</sup> have shown that 2% isoflurane treatment for 6 h long can cause apoptosis. Their study was conducted on cell cultures, primary neurons and mice. They stated that isoflurane can increase the pro-apoptotic Bax factor level, decrease the anti-apoptotic Bcl-2 factor level, increase the accumulation of reactive oxygen species, enable the release of cytochrome c from mitochondria in cytosol and induce the activation of caspase-9 and caspase-3, thus inducing apoptosis through Bcl-2 protein family and mitochondrial path.

Wei et al.<sup>26</sup> propose another hypothesis: activation of inositol 1,4,5-triphosphate (IP<sub>3</sub>) receptors on the endoplasmic reticulum membranes by isoflurane. This fact causes the excessive release of calcium, triggering apoptosis. The authors specify that isoflurane induced apoptosis, dependent on the anesthetic concentration and duration, increasing the cytosolic and then the mitochondrial calcium. Turrilazzi et al.<sup>27</sup> report a case of fatal fulminant hepatic necrosis after sevoflurane anesthesia, incriminating the cytoplasmic calcium increase by sevoflurane as cause.

In conclusion, our results show that sevoflurane does not trigger hepatocyte apoptosis, whereas isoflurane determines a moderate inconstant peri-acinar apoptosis, 24 h post-anesthesia. Our results suggest that the tested anesthetics do not present a significant hepatotoxicity, sevoflurane proving to have a superior tolerability in comparison to isoflurane.

## Conflicts of interest

The authors declare no conflicts of interest.

## Acknowledgement

This paper was published under the frame of European Social Fund, Human Resources Development Operational Programme 2007–2013, project no. POSDRU/159/1.5/S/136893

## References

- Lewis JCM. Field use of isoflurane and air anesthetic equipment in wildlife. *J Zoo Wildl Med.* 2004;35:303–11.
- Wimsatt J, O'shea TJ, Ellison LE, et al. Anesthesia and blood sampling of wild big brown bats (*Eptesicus fuscus*) with and assessment of impacts on survival. *J Wildl Dis.* 2005;41:87–95.
- Parker WT, Muller LI, Gerhardt RR, et al. Field use of isoflurane for safe squirrel and woodrat anesthesia. *J Wildl Manage.* 2008;72:1262–6.
- Escobar A, Thiesen R, Vitaliano SN, et al. Some cardiopulmonary effects of sevoflurane in crested caracara (*Caracara plancus*). *Vet Anaesth Analg.* 2009;36:436–41.
- Granone TD, De Francisco ON, Killos MB, et al. Comparison of three different inhalant anesthetic agents (isoflurane, sevoflurane, desflurane) in red-tailed hawks (*Buteo jamaicensis*). *Vet Anaesth Analg.* 2012;39:29–37.
- Waskell L. Metabolism of the volatile anesthetics. In: Rice SA, Fish KJ, editors. *Anesthetic toxicity.* New York: Raven Press; 1994. p. 49.
- Baden JM, Rice SA. Metabolism and toxicity of inhaled anesthetics. In: Miller RD, editor. *Anesthesia.* 5th ed. New York: Churchill Livingstone; 2000. p. 147–73.
- Brunt EM, White H, Marsh JW, et al. Fulminant hepatic failure after exposure to isoflurane anesthesia: a case report. *Hepatology.* 1991;13:1017–21.
- Zizek D, Ribnikar M, Zizek B, et al. Fatal subacute liver failure after repeated administration of sevoflurane anaesthesia. *Eur J Gastroenterol Hepatol.* 2010;22:112–5.
- Soubhia AF, Lauz S, Montero EF, et al. Effects of the inhalational anesthetics halothane and sevoflurane on an experimental model of hepatic injury. *Rev Bras Anesthesiol.* 2011;61:591–603.
- Sahin SH, Cinar SO, Paksoy I, et al. Comparison between low flow sevoflurane anesthesia and total intravenous anesthesia during intermediate-duration surgery: effects on renal and hepatic toxicity. *Hippokratia.* 2011;15:69–74.
- Byles PH, Dobkin AB, Ferguson JH, et al. Forane (compound 469): 2. Biochemical effects of repeated administration to animals, response to bleeding, and compatibility with epinephrine. *Can Anaesth Soc J.* 1971;18:387–96.
- Steffey EP, Zinkl J, Howland D Jr. Minimal changes in blood cell counts and biochemical values associated with prolonged isoflurane anesthesia of horses. *Am J Vet Res.* 1979;40:1646–8.
- Eger EI 2nd. Isoflurane: a review. *Anesthesiology.* 1981;55:559–76.
- Honda M, Yamada T, Nomura T, et al. Differential, histochemical and immunohistochemical changes in rat hepatocytes after isoflurane or sevoflurane exposure. *Acta Med Okayama.* 2003;57:1–12.
- Elena G, Amerio N, Ferrero P, et al. Effects of repetitive sevoflurane anaesthesia on immune response, select biochemical parameters and organ histology in mice. *Lab Anim.* 2003;37:193–203.
- Carrigan TW, Straughen WJ. A report of hepatic necrosis and death following isoflurane anesthesia. *Anesthesiology.* 1987;67:581–3.
- Mazze RI, Rice SA, Baden JM. Halothane, isoflurane and enflurane MAC in pregnant and nonpregnant female and male mice and rats. *Anesthesiology.* 1985;62:339–41.
- Tamada M, Inoue T, Watanabe Y, et al. MAC values of sevoflurane. *Prog Med.* 1986;6:3248–53 (in Japanese with English abstract).
- Jubb KVF, Kennedy PC, Palmer N. Pathology of domestic animals, vol. 2, 3rd ed. Academic Press, Inc.; 1985. p. 240–307.
- Treuting PM, Dintzis SM. Comparative Anatomy and Histology: A Mouse and Human Atlas. United States of America: Academic Press; 2012. p. 193–9 [chapter 13].
- Nishiyama T, Yokoyama T, Hanaoka K. Liver and renal function after repeated sevoflurane or isoflurane anaesthesia. *Can J Anaesth.* 1998;45:789–93.
- Nishiyama T. Effects of repeat exposure to inhalation anesthetics on liver and renal function. *J Anaesthesiol Clin Pharmacol.* 2013;29:83–7.
- Kerr JF. Shrinkage necrosis: a distinct mode of cellular death. *J Pathol.* 1971;105:13–20.
- Zhang Y, Dong Y, Wu X, et al. The mitochondrial pathway of anesthetic isoflurane-induced apoptosis. *J Biol Chem.* 2010;285:4025–37.
- Wei H, Liang G, Yang H, et al. The common inhalational anesthetic isoflurane induces apoptosis via activation of inositol 1,4,5-triphosphate receptors. *Anesthesiology.* 2008;108:251–60.
- Turrilazzi E, D'errico S, Neri M, et al. A fatal case of fulminant hepatic necrosis following sevoflurane anesthesia. *Toxicol Pathol.* 2007;35:780–5.