



REVISTA BRASILEIRA DE ANESTESIOLOGIA

Publicação Oficial da Sociedade Brasileira de Anestesiologia
www.sba.com.br



SCIENTIFIC ARTICLE

Bilateral greater occipital nerve block for treatment of post-dural puncture headache after caesarean operations



Esra Uyar Türkyilmaz^{a,*}, Nuray Camgöz Eryilmaz^a, Nihan Aydın Güzey^a,
Özlem Moraloğlu^b

^a Zekai Tahir Burak Womens' Health Training and Research Hospital, Department of Anesthesiology and Reanimation, Ankara, Turkey

^b Zekai Tahir Burak Womens' Health Training and Research Hospital, Department of Obstetrics and Gynecology, Ankara, Turkey

Received 3 December 2014; accepted 23 March 2015

Available online 21 January 2016

KEYWORDS

Post-dural puncture headache;
Caesarean operations;
GON block

Abstract

Background: Post-dural puncture headache (PDPH) is an important complication of neuroaxial anesthesia and more frequently noted in pregnant women. The pain is described as severe, disturbing and its location is usually fronto-occipital. The conservative treatment of PDPH consists of bed rest, fluid therapy, analgesics and caffeine. Epidural blood patch is gold standard therapy but it is an invasive method. The greater occipital nerve (GON) is formed of sensory fibers that originate in the C2 and C3 segments of the spinal cord and it is the main sensory nerve of the occipital region. GON blockage has been used for the treatment of many kinds of headache. The aim of this retrospective study is to present the results of PDPH treated with GON block over 1 year period in our institute.

Methods: 16 patients who had been diagnosed to have PDPH, and performed GON block after caesarean operations were included in the study. GON blocks were performed as the first treatment directly after diagnose of the PDPH with levobupivacaine and dexamethasone.

Results: The mean VAS score of the patients was 8.75 (± 0.93) before the block; 3.87 (± 1.78) 10 min after the block; 1.18 (± 2.04) 2 h after the block and 2.13 (± 1.64) 24 h after the block. No adverse effects were observed.

Conclusions: Treatment of PDPH with GON block seems to be a minimal invasive, easy and effective method especially after caesarean operations. A GON block may be considered before the application of a blood patch.

© 2015 Sociedade Brasileira de Anestesiologia. Published by Elsevier Editora Ltda. This is an open access article under the CC BY-NC-ND license (<http://creativecommons.org/licenses/by-nc-nd/4.0/>).

* Corresponding author.

E-mail: esrauyarturkyilmaz@yahoo.com (E. Uyar Türkyilmaz).

PALAVRAS-CHAVE

Cefaléia pós-punção dural;
 Cesarianas;
 Bloqueio do NOM

Bloqueio bilateral do nervo occipital maior para tratamento de cefaleia pós-punção dural após cesarianas

Resumo

Justificativa: A cefaleia pós-punção dural (CPPD) é uma complicação importante da anestesia neuroaxial e mais frequentemente observada em mulheres grávidas. A dor é descrita como intensa, perturbadora, e sua localização é geralmente fronto-occipital. O tratamento conservador da CPPD consiste em repouso no leito, fluidoterapia, analgésicos e cafeína. O tampão sanguíneo peridural é o padrão ouro de tratamento, mas é um método invasivo. O nervo occipital maior (NOM) é formado por fibras sensoriais com origem nos segmentos C2 e C3 da medula espinhal e é o principal nervo sensorial da região occipital. O bloqueio do NOM tem sido usado para o tratamento de muitos tipos de dor de cabeça. O objetivo deste estudo retrospectivo foi apresentar os resultados de CPPD tratada com bloqueio do NOM no período de um ano em nosso instituto.

Métodos: 16 pacientes que foram diagnosticadas com CPPD e submetidas a bloqueio de NOM após cesariana foram incluídas no estudo. Os bloqueios do NOM foram realizados como o primeiro tratamento imediatamente após o diagnóstico de CPPD com levobupivacaína e dexametasona.

Resultados: A média dos escores EVA das pacientes foi de 8,75 ($\pm 0,93$) antes do bloqueio; 3,87 ($\pm 1,78$) 10 minutos após o bloqueio; 1,18 ($\pm 2,04$) 2 horas após o bloqueio e 2,13 ($\pm 1,64$) 24 horas após o bloqueio. Efeitos adversos não foram observados.

Conclusões: O tratamento da CPPD com bloqueio do NOM parece ser um método minimamente invasivo, fácil e eficaz, especialmente após cesarianas. O bloqueio do NOM pode ser considerado antes da aplicação de um tampão sanguíneo peridural.

© 2015 Sociedade Brasileira de Anestesiologia. Publicado por Elsevier Editora Ltda. Este é um artigo Open Access sob uma licença CC BY-NC-ND (<http://creativecommons.org/licenses/by-nc-nd/4.0/>).

Introduction

Post-dural puncture headache (PDPH) is an disturbing complication of neuroaxial anesthesia and occurs approximately in 1.5% of cases ranging from 0.19% to 3.6% in different units.¹ PDPH is more frequently noted in pregnant women receiving neuroaxial anesthesia.² The typical location of the headache is usually bifrontal and/or occipital. It is described as severe, disturbing and debilitating pain that is increasing in the upright position while decreasing or completely disappearing in the supine position.³ According to the International Headache Society, headache develops within 5 days after the dural puncture and resolves either spontaneously within 7 days or within 48 h after effective treatment of the spinal fluid leak.⁴ The conservative treatment of PDPH usually consists of fluid therapy, analgesics and caffeine. Epidural blood patch (EBP) is gold standard therapy but it is an invasive method.

The greater occipital nerve (GON) is formed of sensory fibers that originate in the C2 and C3 segments of the spinal cord.⁵ It is the main sensory nerve of the occipital region. GON blockage has been used successfully for the treatment of cervicogenic headache, occipital neuralgia, cluster headache, and migraine.^{5,6} Accompanying clinical symptoms of PDPH are very similar to those of cervicogenic headache that have been effectively treated with occipital nerve blockade.⁷ GON block is reported to be used for treatment of PDPH in individual cases and in one controlled study.⁸⁻¹⁰ The aim of this retrospective study is to present

the results of PDPH treated with GON block over 1 year period in our institute.

Methods

After the improvement of Local Ethics Committee, the patients who had been diagnosed to have PDPH, and performed GON block as the first choice treatment after caesarean operations were determined from the anesthesia department records and included in the study. The following parameters had been received from the anesthesia department records: the type and diameter of the needle, the time when the headache started postoperatively and when the GON block performed, the visual analog score (VAS) of the patients before the GON block, 10 min, 2 h and 24 h after the GON block. If there is an increment in intensity of pain at the evaluation at 24th hour; time of increment of pain, VAS after the increment of pain, any need for a second block. If a second block is performed; VAS of the patients 2 h and 24 h after the second GON block

All the headaches occurring after regional anesthesia are firstly evaluated by anesthesia department. For the diagnosis of PDPH, the criteria established by International Headache Society had been used.¹¹ The diagnostic criteria is as follows: (1) headache: (a) worsens within 15 min of sitting or standing; (b) improves within 15 min after lying down; (c) must have one of the following: (i) neck stiffness; (ii) tinnitus; (iii) hypacusia; and (iv) photophobia; (2) dural puncture has been performed; (3) headache develops within 5 days

after dural puncture; and (4) headache resolves: (a) spontaneously within 1 week (95% of cases); and (b) within 48 h after epidural blood patch (EBP). All the patients who had been diagnosed to have PDPH were informed about conservative therapy, EBP and GON block. Patients who refused bed rest, demanded early mobilization and also refused an EBP as a first choice treatment were informed about GON block and it had been emphasized to these patients that this was not a routine treatment for PDPH. Before the block, informed consent was obtained from the patients, explaining that the procedure was not routine treatment. As GON block is not a routine treatment for postdural puncture headache, the patients were observed closely and during GON block period the records were kept strictly.

GON blocks were performed as the first treatment directly after diagnose of the PDPH. All the blocks were performed by the same two anesthesiologist who had ten years experience in anesthesia. Following routine monitorization (blood pressure, pulse oximetry, 3-lead electrocardiogram), an iv access was secured. Bilateral blockade of the GON was performed by the method which is based on the anatomical landmarks. The GON is located approximately two thirds of the distance on a line drawn from the center of the mastoid to the external occipital protuberance (Fig. 1).^{12,13} External occipital protuberance (EOP) was palpated and a needle was inserted between 15 mm and 25 mm lateral to the EOP parallel to the superior nuchal line. 2.5 mL of treatment solution was injected each side. The treatment solution consisted of levobupivacaine 2.5 mg mL⁻¹ (Chirocaine 50 mg/10 mL ampoule, Abbott) and dexamethasone 1 mg mL⁻¹ (Onadron 8 mg/2 mL ampoules, İ.E. Ulagay İlaç Sanayii Türk A.Ş.). A second block was performed if the VAS score is higher than 3. If second block is performed, only levobupivacaine 2.5 mg mL⁻¹ (Chirocaine 50 mg/10 mL ampoule, Abbott) without dexamethasone was used. Sensory changes such as numbness or sensory loss of the dermatome was checked after the GON block. If there were

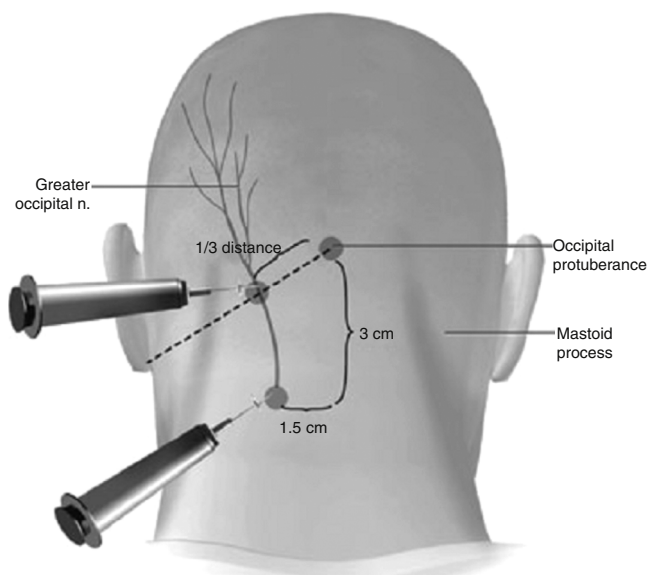


Figure 1 The GON located approximately two thirds of the distance on a line drawn from the center of the mastoid to the external occipital protuberance.

Table 1 Demographic characteristics of the patients.

	Mean \pm SD
Age (years)	29.87 (\pm 3.84)
Height (cm)	163.87 (\pm 4.19)
Weight (kg)	74.34 (\pm 3.40)
BMI (kg m ⁻²)	27.73 (\pm 1.36)

no sensory changes, it was decided that the block was failed. Together with GON blockade, oral hydration had been commenced. Vasovagal syncopal attack, transient dizziness following the injection, intravascular injection of the local anesthetic solution are reported as adverse effects of GON block.^{14,15} Any adverse effects during and after the block were recorded. Patients were examined on the third and seventh day after the block.

Results

In our institution 7864 patients had underwent spinal anesthesia for caesarean operations between January and December 2013. 289 patients had been evaluated for headache. 213 patients had been diagnosed to have PDPH. Conservative therapy had been used for 188 patients, EBP had been used for 9 patients and GON block had been used for 16 patients as the first choice treatment. Among the patients who had been threatened with conservative therapy; 92 patients had adequate analgesia, 73 patients had inadequate analgesia but refused any other therapeutic options and EBP was used for 23 patients.

All of our patients received spinal anesthesia for caesarean operation. The demographical characteristics of the patients are detailed in Table 1. None of our patients had preeclampsia, history of headache or any neurological disorder. Spinal blocks are performed using 26 gauge needles with an atraumatic bevel (Atraucan®, B-Braun, Germany). No complications occurred during the operations. The mean duration for the start of the complaints of the typical symptoms of PDPH was 34.37 (\pm 17.11) h after dural puncture. The mean duration for performing GON block was 44.06 (\pm 20.01) h after dural puncture.

The mean VAS score of the patients was 8.75 (\pm 0.93) before the block; 3.87 (\pm 1.78) 10 min after the block; 1.18 (\pm 2.04) 2 h after the block and 2.13 (\pm 1.64) 24 h after the block. At the evaluation at 24th hour, there was an increment in intensity of pain of 6 patients. The mean time for increment in pain intensity was 17.71 (\pm 3.77) h after the GON block. Only 2 of these 6 patients had VAS scores higher than 3 and needed a second block. The VAS scores of the rest were lower than or equal to 2. At the evaluation 2 h and 24 h after the second block, these patients' VAS scores were lower than 2. One patient's VAS score did not change two hours after primary GON block and an EBP is performed to this patient (Table 2). No adverse effects were observed. At the evaluation on the third day and seventh day of the GON block, none of the patients needed any other treatment option (the VAS scores of all the patients were 0 or less than 2). None of the patients reported any adverse events.

Table 2 The onset time, GON block time, painless duration and the intensity of pain.

N	Start of pain after dural puncture (h)	GON block time (h)	VAS1	VAS2	VAS3	VAS4	Time of increment in pain intensity (after GON block) (h)	2nd GON block time (after increment of pain intensity) (h)	VAS5	VAS6
1	48	50	9	2	0	0	-	-	-	-
2	24	26	8	3	2	2	-	-	-	-
3	72	96	8	1	0	0	-	-	-	-
4	12	26	8	4	2	2	-	-	-	-
5	20	25	7	2	0	2	20	-	-	-
6	20	24	9	2	0	2	16	-	-	-
7	36	40	9	2	0	5	13	8	1	0
8	12	28	8	5	0	2	24	-	-	-
9	48	52	10	4	2	2	-	-	-	-
10	24	26	10	8	8		-	-	-	-
11	24	31	10	4	0	2	20	-	-	-
12	36	49	8	5	1	0	-	-	-	-
13	30	48	10	5	0	3	15	-	-	-
14	36	50	8	5	0	6	16	10	2	0
15	48	52	9	5	2	2	-	-	-	-
16	60	82	9	5	2	2	-	-	-	-

VAS1, VAS before GON block; VAS2, VAS 10 minutes after GON block; VAS3, VAS 2 hours after GON block; VAS4, VAS 24 hours after GON block; VAS5, VAS 2 hours after the second GON block; VAS6, VAS 24 hours after second GON block.

Discussion

Loss of cerebro spinal fluid (CSF) through dural hole results in a decrease in CSF volume and pressure. This CSF volume and pressure loss may cause downward traction on the pain-sensitive intracranial veins and meninges, as well as the cranial nerves.^{3,8} It is not possible to explain PDPH only with traction theory. The bimodal theory suggests that there is a combination of both low CSF pressure and resultant cerebral vasodilatation in reaction to the stretching of vessels.² Pregnant women are particularly prone to PDPH.^{16,17} Additionally, the intensity of PDPH in obstetric patients is reported to be significantly higher compared with the other patients.¹⁸

The conservative treatment of PDPH consists of bed rest, non-steroidal anti-inflammatory drugs (NSAIDs), caffeine and weak opioid analgesics. A decrease in the duration and severity of headache, need for any other therapeutic option (e.g. EBP), improvement of daily activity is expected from the treatment modality. Whereas, Sprigge et al. reported that bed rest and mild analgesics did not give effective pain relief for more than 14% of patients suffered from PDPH.¹⁹ Studies comparing the effects of conventional medical treatment and EBP, report that results did not evidence any reduction of pain during the 24 hours of follow up in the conventional medical treatment group¹⁸ and more patients in the EBP group felt better at 24 h compared with the conservative group (89% vs. 19%).²⁰ Bed rest does not appear to affect the course of PDPH.^{21,22} One recent meta analysis showed that the efficacy of oral and IV caffeine administration was of no benefit.²³

The most effective treatment for PDPH is EBP, which involves the injection of autologous blood into the epidural space. EBP is an invasive method and has many side effects. It may contribute to development of back pain, lumbar vertebral syndrome, transient bradycardia, and an increase in

body temperature.²⁴ Longer term complications are rare but examples include meningitis, arachnoiditis, lumbovertebral syndrome and radicular pain.²⁵

Therapeutic epidural blood patch reported to decrease PDPH and severe PDPH over conservative treatment.²⁶ The cumulative probability of complete recovery was 84% after 1 week in patients allocated to EBP and 14% in patients allocated to conservative treatment.²⁰

Although an epidural blood patch remains the definitive treatment for PDPH, surveys about the management of PDPH in different units and countries present that most respondents first treated the patients conservatively. In surveys about UK, German and Turkish practice; 71%, 94.5% and 64% of responders are reported to perform EBP after the failure of conservative measures respectively.²⁷⁻²⁹ National Obstetric Anesthetic Database showed that EBP was performed within two days of delivery in only 42% women.³⁰ In this situation, as mentioned above many patients are left to a relatively low effective treatment period. Any other treatment modality which is more effective than conservative treatment and less invasive than EBP is seems to be needed.

A possible treatment method for PDPH is GON blockade. The rationale for using greater occipital nerve block comes from the proximity of sensory neurons in the upper cervical spinal cord to the trigeminal nucleus caudalis (TNC) neurons and the convergence of sensory input to TNC neurons from both cervical and trigeminal fibres.³¹ The convergence within the trigeminocervical nucleus allows the bidirectional exchange of sensory information between the trigeminal and the upper cervical spinal nerves.³² Since the branch of greater occipital nerve arising from C2 root is responsible for the innervation of deep paraspinal muscles and suboccipital configurations, greater occipital nerve blockade inhibits the stimulations arising from these regions innervated by the greater occipital nerve.³³ This blockade ensures the interruption of pain transmission via the occipital nerves or their

component nerve roots or ganglia. The analgesia obtained after the block may be explained by the central neuromodulatory effect that causes decreased central sensitization as a result of the temporary interruption of afferent input to the dorsal roots and trigeminal nucleus.³⁴ It is not clear why, considering the etiology, the headache stopped definitively. Reducing nociceptive traffic through a temporary neural blockade in a sensitized system may allow "winding-down" of central sensitization. Ongoing pain on the basis of peripheral sensitization could also be enhanced through the same process.¹² Neurological examinations and radiological investigations should be considered in persistent post-spinal cases so that neurological complications can be ruled out.

We observed that the GON blockade was effective in stopping PDPH after caesarean operations. The mean VAS score of the patients was 8.75 (± 0.93) before the block; 3.87 (± 1.78) 10 min after the block; 1.18 (± 2.04) 2 h after the block and 2.13 (± 1.64) 24 h after the block. Only one of our patients had neither sensory loss of the dermatome nor a decrease at VAS score 10 min and 2 h after block, this was evaluated failure of the block and the patient was convinced for EBP. The pain of this patient stopped after EBP. Our results are consistent with the previously reported cases and a study comparing the effects of GON block with conventional therapy.

Matute et al.⁸ reported the effect of bilateral GON blockage on PDPH with 2 cases. Neither patient had responded to conservative treatment then a block was performed using a mixture of 4 mL 0.25% bupivacaine and 20 mg triamcinalone. The pain resolved within 1–2 min and the patients were discharged 48 h later. Takmaz et al.⁹ reported a case in which a PDPH did not respond to conservative therapy and resolved within 2 min with a GON block performed with 2 mL of 0.5% bupivacaine. 12 h after the block, he reported mild pain that did not restrict his daily activity. The blocks were repeated, where upon his pain completely disappeared. Naja et al.¹⁰ compared the effect of bilateral GON blockage on PDPH with conventional treatment and reported that the pain resolved completely using 1 or 2 injections in 68% of the patients while the remaining 32% required 3 or 4 injections. We used a mixture of levobupivacaine 0.25% and dexamethasone 1 mg mL⁻¹ and injected 2.5 mL each side. It is mentioned that local anesthetics with steroid was more effective than local anesthetic alone for suboccipital injection.³⁵

It is important to stop PDPH especially after caesarean operations because it often interferes with maternal-infant interaction. The patients are most comfortable when they are in supine position but much obstetric patient is unable to do this because of the newborn baby. It is reported in a study designed to investigate the patient experience following accidental dural puncture complicating obstetric epidural analgesia that, after headache, bed rest was a major complaint of the patients; many patients could only get relief from their headache when supine but found nursing and feeding a baby extremely difficult when prostrate; 47% patients complained that being confined to bed was the worst aspect.³⁶ In our study group after application of GON block, patients were mobilized and could be able to nurse and breastfeed their babies easily. For this reason, GON blockade is seems to be more useful after caesarean operations compared with other surgery types.

GON block is used for different types of headaches, its adverse effects are previously evaluated.¹⁴ The adverse effects of GON block are reported as vasovagal syncopal attack, transient dizziness following the injection, alopecia around the injection site and exaggerated headache.¹⁵ Greater occipital nerve has superficial location leading to lesser complications; however, there is intravascular injection risk, which can be reduced by careful aspiration. None of these occurred in our 16 patients. Alopecia around the injection side is a longer time complication; we made explanation about this complication to our patients, no patient appealed with the complaint of alopecia.

One of the limitations of our study is lack of control group. The effectiveness of GON block could be compared with the conservative therapy but in our institution the records of the patients who had been threatened with conservative therapy had not been kept as strict as the patients who had been threatened with GON block. A controlled randomized study is needed for comparing the efficiency of the methods. Another limitation of our study is the possibility of investigator bias.

In conclusion, treatment of PDPH with GON block is seems to be a minimal invasive, easy and effective method especially for patients like new mothers A GON block may be considered before the application of a blood patch. Well-designed controlled studies are needed to assess the role of GON block in the treatment of PDPH.

Conflicts of interest

The authors declare no conflicts of interest.

References

1. Choi PT, Galinski SE, Takeuchi L, et al. PDPH is a common complication of neuroaxial blockade in parturients: a meta-analysis of obstetrical studies. *Can J Anaesth.* 2003;50:460–9.
2. Candido KD, Stevens RA. Post-dural puncture headache: pathophysiology, prevention and treatment. *Best Pract Res Clin Anaesthesiol.* 2003;17:451–69.
3. Turnbull DK, Shepherd DB. Post-dural puncture headache: pathogenesis, prevention and treatment. *Br J Anaesth.* 2003;91:718–29.
4. Amorim JA, Gomes de Barros MV, Valenc MM. Post-dural (post-lumbar) puncture headache: risk factors and clinical features. *Cephalalgia.* 2012;32:916–23.
5. Anthony M. Cervicogenic headache: prevalence and response to local steroid therapy. *Clin Exp Rheumatol.* 2000;18:59–64.
6. Peres MFP, Stiles MA, Siow HC, et al. Greater occipital nerve blockade for cluster headache. *Cephalalgia.* 2002;22:520–2.
7. Naja ZM, El-Rajab M, Al-Tannir MA, et al. Occipital nerve blockade for cervicogenic headache: a double-blind randomized controlled clinical trial. *Pain Pract.* 2006;6:89–95.
8. Matute E, Bonilla S, Girones A, et al. Bilateral greater occipital nerve block for post-dural puncture headache. *Anaesthesia.* 2008;63:551–60.
9. Takmaz S, Ünal KÇ, Kaymak Ç, et al. Treatment of post-dural puncture headache with bilateral greater occipital nerve block. *Headache.* 2010;50:869–81.
10. Akin Takmaz S, Unal Kantekin C, Kaymak C, et al. Nerve stimulator-guided occipital nerve blockade for postdural puncture headache. *Pain Pract.* 2009;9:51–8.

11. Headache Classification Subcommittee of the International Headache Society. The International Classification of Headache Disorders: 2nd edition. Cephalalgia. 2004;24:9–160.
12. Levin M. Nerve blocks in the treatment of headache. Neurotherapeutics. 2010;7:197–203.
13. Young WB, Marmura M, Ashkenazi A, et al. Greater occipital nerve and other anesthetic injections for primary headache disorders. Headache. 2008;48:1122–5.
14. Tobin J, Flitman S. Occipital nerve blocks: when and what to inject? Headache. 2009;49:1521–33.
15. Afridi SK, Shields KG, Bhola R, et al. Greater occipital nerve injection in primary headache syndromes – prolonged effects from a single injection. Pain. 2006;122:126–9.
16. Paech M, Banks S, Gurrin L. An audit of accidental dural puncture during epidural insertion of a Tuohy needle in obstetric patients. Int J Obstet Anesth. 2001;10:162–7.
17. Kuczkowski KM. Post dural puncture headache in the obstetric patient: an old problem. New solutions. Minerva Anesthesiol. 2004;70:823–30.
18. Sandesc D, Lupei MI, Sirbu C, et al. Conventional treatment or epidural blood patch for the treatment of different etiologies of post dural puncture headache. Acta Anaesthesiol Belg. 2005;56:265–9.
19. Sprigge JS, Harper SJ. Accidental dural puncture and post dural puncture headache in obstetric anaesthesia: presentation and management: a 23-year survey in a district general hospital. Anaesthesia. 2008;63:36–43.
20. van Kooten F, Oedit R, Bakker SLM, et al. Epidural blood patch in post dural puncture headache: a randomised, observer-blind, controlled clinical trial. J Neurol Neurosurg Psychiatry. 2008;79:553–8.
21. Arevalo-Rodriguez I, Ciapponi A, Munoz L, et al. Posture and fluids for preventing post-dural puncture headache. Cochrane Database Syst Rev. 2013;12:7.
22. Choi PT, Galinski SE, Lucas S, et al. Examining the evidence in anesthesia literature: a survey and evaluation of obstetrical postdural puncture headache reports. Can J Anaesth. 2002;49:49–56.
23. Halker RB, Demaerschalk BM, Wellik KE, et al. Caffeine for the prevention and treatment of postdural puncture headache: debunking the myth. Neurologist. 2007;13:323–7.
24. Oh J, Camann W. Severe, acute meningeal irritative reaction after epidural blood patch. Anesth Analg. 1998;87:1139–40.
25. Boyle JAH, Stocks GM. Post-dural puncture headache in the parturient – an update. Anaesthesia Intens Care Med. 2010;11:302–4.
26. Boonmak P, Boonmak S. Epidural blood patching for preventing and treating post-dural puncture headache. Cochrane Database Syst Rev. 2010.
27. Baraz R, Collins RE. The management of accidental dural puncture during labour epidural analgesia: a survey of UK practice. Anaesthesia. 2005;60:673–9.
28. Marcus HE, Fabian A, Dagtekin O, et al. Pain, postdural puncture headache, nausea and pruritis after cesarean delivery: a survey of prophylaxis and treatment. Minerva Anesthesiol. 2011;77:1043–9.
29. Gunaydin B, Camgoz N, Karaca G, et al. Survey of Turkish practice evaluating the management of postdural puncture headache in the obstetric population. Acta Anaesthesiol Belg. 2008;59:7–14.
30. Chan TML, Ahmed E, Yentis SM, et al. Postpartum headaches: summary report of the National Obstetric Anesthetic Database (NOAD) 1999. Int J Obstet Anesth. 2003;12:107–12.
31. Ashkenazi A, Levin M. Greater occipital nerve block for migraine and other headaches: is it useful? Curr Pain Headache Rep. 2007;11:231–5.
32. Biondi DM. Cervicogenic headache: a review of diagnostic and treatment strategies. J Am Osteopath Assoc. 2005;105 Suppl. 2:16S–22S.
33. Akyol F, Binici O, Çakır M. Ultrasound-guided bilateral greater occipital nerve block for the treatment of postdural puncture headache. Turk J Anaesth Reanim. 2014;42:40–2.
34. Bartsch T, Goadsby PJ. Stimulation of the greater occipital nerve induces increased central excitability of dural afferent input. Brain. 2002;125:1496–509.
35. Ambrosini A, Vandenheede M, Rossi P, et al. Suboccipital injection with a mixture of rapid- and long-acting steroids in cluster headache: a double blind placebo-controlled study. Pain. 2005;118:92–6.
36. Costigan SN, Sprigge JS. Dural puncture: the patients' perspective. A patient survey of cases at a DGH maternity unit 1983–1993. Acta Anaesthesiol Scand. 1996;40:710–4.