



## CASE REPORTS

# Anesthetic management in a patient with arrhythmogenic right ventricular cardiomyopathy and an implantable cardioverter defibrillator: a case report



Yoko Ohyama<sup>a,b</sup>, Hiroshi Hoshijima<sup>id b,\*</sup>, Hiroshi Nagasaka<sup>b</sup>, Jun Shimada<sup>a</sup>

<sup>a</sup> Meikai University School of Dentistry, Department of Diagnostic and Therapeutic Sciences, First Division of Oral and Maxillofacial Surgery, Sakado-Shi, Japan

<sup>b</sup> Saitama Medical University Hospital, Department of Anesthesiology, Moroyama-Machi, Iruma-Gun, Japan

Received 7 June 2019; accepted 15 February 2020

Available online 28 April 2020

### KEYWORDS

Arrhythmogenic right ventricular cardiomyopathy; Ventricular tachycardia; Implantable cardioverter defibrillator

### Abstract

**Background and objectives:** Arrhythmogenic right ventricular cardiomyopathy (ARVC) is a genetic cardiomyopathy characterized by potentially lethal ventricular tachycardia. Here we describe a patient with ARVC and an Implantable Cardioverter Defibrillator (ICD) in whom maxillary sinus surgery was performed under general anesthesia.

**Case report:** The patient was a 59 year-old man who was scheduled to undergo maxillary sinus surgery under general anesthesia. He had been diagnosed as having ARVC 15 years earlier and had undergone implantation of an ICD in the same year. Electrocardiography showed an epsilon wave in leads II, aVR, and V1–V3. Cardiac function was within normal range on transthoracic echocardiography. The ICD was temporarily deactivated after the patient arrived in the operating room and an intravenous line was secured. An external defibrillator was kept on hand for immediate defibrillation if any electrocardiographic abnormality was detected. Remifentanyl 0.3 µg/kg/min, fentanyl 0.1 mg, propofol 154 mg, and rocuronium 46 mg were administered for induction of anesthesia. Tracheal intubation was performed orally. Anesthesia was maintained oxygen 1.0 L.min<sup>-1</sup>, air 2.0 L.min<sup>-1</sup>, propofol 5.0–7.0 mg.kg<sup>-1</sup>.h<sup>-1</sup>, and remifentanyl 0.1–0.25 µg.kg<sup>-1</sup>.min<sup>-1</sup>. The surgery was completed as scheduled and the ICD was reactivated. The patient was then extubated after administration of sugammadex 200 mg.

**Conclusion:** We report the successful management of anesthesia without lethal arrhythmia in a patient with ARVC and an ICD. An adequate amount of analgesia should be administered during general anesthesia to maintain adequate anesthetic depth and to avoid stress and pain.

© 2020 Sociedade Brasileira de Anestesiologia. Published by Elsevier Editora Ltda. This is an open access article under the CC BY-NC-ND license (<http://creativecommons.org/licenses/by-nc-nd/4.0/>).

\* Corresponding author.

E-mail: [hhoshi@saitama-med.ac.jp](mailto:hhoshi@saitama-med.ac.jp) (H. Hoshijima).

**PALAVRAS-CHAVE**

Cardiomiopatia arritmogênica do ventrículo direito; Taquicardia ventricular; Cardioversor desfibrilador implantável

**Anestesia para paciente com cardiomiopatia arritmogênica do ventrículo direito portador de cardioversor desfibrilador implantável: descrição de caso****Resumo**

*Introdução e objetivo:* A Cardiomiopatia Arritmogênica do Ventrículo Direito (CAVD) é uma cardiomiopatia genética caracterizada por taquicardia ventricular potencialmente letal. Descrevemos um paciente com CAVD com Cardioversor Desfibrilador Implantável (CDI) submetido a anestesia geral para cirurgia de seio maxilar.

*Relato do caso:* Paciente masculino, 59 anos, a ser submetido a anestesia geral para cirurgia de seio maxilar. O paciente foi diagnosticado com CAVD há 15 anos, momento em que foi submetido a implante de CDI. A eletrocardiografia mostrou onda épsilon nas derivações II, aVR e V1–V3. O ecocardiograma transtorácico revelou função cardíaca normal. Após a entrada do paciente na sala de cirurgia, o CDI foi temporariamente desativado e uma via intravenosa foi instalada. Um desfibrilador externo foi mantido próximo ao paciente caso fosse detectada alguma anormalidade eletrocardiográfica que indicasse desfibrilação do paciente. Foram administrados 0,3 mg/kg/min de remifentanil, 0,1 mg de fentanil, 154 mg de propofol e 46 mg de rocurônio para indução da anestesia. A intubação traqueal foi realizada por via oral. A anestesia foi mantida com 1 L/min de oxigênio, 2 L/min de ar, 5–7 mg/kg/h de propofol e 0,1–0,25 µg/kg/min de remifentanil. O procedimento cirúrgico proposto foi concluído e o CDI foi reativado. O tubo traqueal foi retirado após administração de 200 mg de sugamadex.

*Conclusão:* Descrevemos técnica de anestesia bem sucedida sem arritmia letal em paciente com CAVD e CDI. Analgesia adequada deve ser administrada durante a anestesia geral para manter profundidade anestésica correta e evitar estresse e dor.

© 2020 Sociedade Brasileira de Anestesiologia. Publicado por Elsevier Editora Ltda. Este é um artigo Open Access sob uma licença CC BY-NC-ND (<http://creativecommons.org/licenses/by-nc-nd/4.0/>).

**Introduction**

Arrhythmogenic Right Ventricular Cardiomyopathy (ARVC) is a genetic degenerative myocardial disease characterized by ventricular fibrillation and Ventricular Tachycardia (VT), an increased risk of sudden death, and fibrofatty replacement of the right ventricle and the subepicardial region of the left ventricle.<sup>1</sup> The epsilon wave is the specific diagnostic electrocardiogram waveform indicative of ARVC. The estimated prevalence of ARVC is 1:5000, and men are more commonly affected than women and at an earlier age.<sup>2</sup>

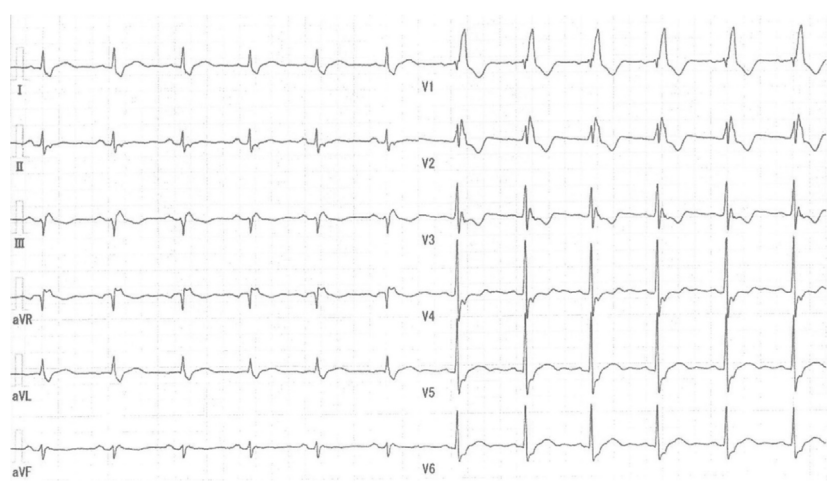
The presenting symptoms are usually palpitations (30%–60%), lightheadedness (20%), and syncope (10%–30%).<sup>1</sup> These symptoms are associated with non-sustained or sustained ventricular arrhythmia. Up to 19% of patients with ARVC present in cardiac arrest.<sup>3</sup> Arrhythmogenic right ventricular dysplasia/cardiomyopathy can occasionally manifest as chest pain and be accompanied by transient ischemic electrocardiographic changes and elevation of troponin, mimicking acute myocarditis or myocardial infarction.

Patients with ARVC are generally sensitive to catecholamines and prone to lethal arrhythmias because of an excessive response to stress. Patients with refractory symptoms undergo implantation of an implantable Cardioverter Defibrillator (ICD). We believe that intraoperative management, including management of general anesthesia, is important in patients with ARVC. We describe the anesthetic management undertaken to prevent the occurrence of lethal arrhythmia in a patient with ARVC and ICD who underwent radical maxillary sinus surgery under general anesthesia.

**Case report**

We obtained consent from the patient for the publication of this case report. The patient was a 59 year-old man (height 171 cm, weight 77 kg) who was scheduled to undergo maxillary sinus surgery under general anesthesia. The patient had been diagnosed as having ARVC at the age of 44 years after three episodes of seizures with loss of consciousness. His electrocardiogram showed epsilon waves in V1–V3 and intensive T waves in V2–V3. Moreover, his onset VT was of the left bundle branch block type. Transthoracic echocardiography showed mild right ventricular dilatation. Biopsy of tissue from the right ventricular wall showed degeneration of the myocardium into adipose tissue. He had no relevant family history, and genetic testing was not performed. An ICD was implanted in his upper right chest in the same year. At the age of 50 years, he experienced an episode of VT with loss of consciousness. The ICD delivered a single effective shock and sinus rhythm was restored. VT had not been detected since that episode. Anti-arrhythmic medication consisted of amiodarone 100 mg/day and carvedilol 2.5 mg/day.

Preoperative electrocardiography showed epsilon waves in leads II, aVR, and V1–V3 (Fig. 1). On transthoracic echocardiography, the left ventricular ejection fraction was 71%, and the right ventricular wall motion was within the normal range. However, slight enlargement of the right ventricular diameter was observed. The ICD settings included pacing for VT, defibrillation for ventricular fibrillation, and VVI mode at 40 per min for anti-bradycardic pacing.



**Figure 1** Electrocardiogram showing an epsilon wave in leads II, aVR, and V1–V3.

The patient's vital signs on arrival in the operating room were Blood Pressure (BP) 146/85 mmHg, Heart Rate (HR) 67 bpm, and SpO<sub>2</sub> = 96%. Bispectral index monitoring (A-3000 Vista; Nihon Kohden, Tokyo, Japan) was also performed via a sensor placed on his forehead. The ICD was temporarily deactivated after the intravenous line was secured. An external defibrillator was kept on hand for immediate use if any electrocardiographic abnormality was detected. Remifentanyl 0.3 µg/kg/min, fentanyl 0.1 mg, and propofol 154 mg were used for induction of anesthesia (BP = 90/58 mmHg, HR = 52 bpm, and SpO<sub>2</sub> = 100%). Tracheal intubation was performed orally after administration of rocuronium 46 mg (BP = 95/63 mmHg, HR = 59 bpm, and SpO<sub>2</sub> = 100%). Anesthesia was maintained with oxygen 1.0 L/min, air 2.0 L/min, propofol 5.0–7.0 mg/kg/h, and remifentanyl 0.1–0.25 µg/kg/min. After induction of anesthesia, 2.0 mL of 2% lidocaine was infiltrated into the operative area, and surgery was begun. Bleeding from the nasal mucosa was noted intraoperatively and controlled using a bipolar electric scalpel. The surgery was completed as scheduled, and the ICD was reactivated. Acetaminophen 1000 mg was administered. The patient was extubated after administration of sugammadex 200 mg. The patient's vital signs at this time were BP = 158/63 mmHg, HR = 85 bpm, and SpO<sub>2</sub> = 100%.

The operating time was 94 min, anesthesia time was 141 min, amount of blood loss was 5 mL, and intraoperative fluid volume administered was 550 mL. Vital signs remained stable, and he was discharged home with no complaints of postoperative pain or mood disturbance. No potentially lethal ventricular arrhythmias were noted during or after surgery.

## Discussion

We achieved successful management of general anesthesia without the occurrence of lethal arrhythmia in a patient with ARVC. First described by Frank et al. in 1978, ARVC is a hereditary degenerative cardiomyopathy that induces potentially lethal arrhythmias. Anesthetic manage-

ment is important in patients with ARVC; however, there is no consensus on the perioperative management of these patients, particularly during general anesthesia.

Patients with ARVC are generally sensitive to catecholamines and prone to lethal arrhythmias because of an exaggerated response to stress. There have been reports of catecholamine-induced VT. Denis et al. reported that administration of high doses of isoproterenol (a beta agonist) to patients with ARVC induced multiple episodes of VT. In a review that investigated mortality in 27 patients with ARVC, 17 deaths coincided with a stressful situation.<sup>4</sup>

Remifentanyl has the effect of significantly suppressing the secretion of epinephrine and norepinephrine, so it is considered effective in suppressing excessive catecholamine release. Therefore, we used a continuous infusion of remifentanyl for both induction and maintenance of anesthesia in our patient to avoid excessive release of catecholamines while monitoring for changes in hemodynamics. We also administered local anesthesia to reduce local pain at the surgical site.

An ICD was already implanted in our patient for secondary prevention of lethal arrhythmia. Care should be taken when performing electrocautery in a patient with an ICD because the electrocautery device can cause the ICD to deliver a shock. These cautionary measures include use of a bipolar electrocautery system if possible, use of short and intermittent bursts of electrocautery at the lowest possible energy levels, and maximizing the distance between the electrocautery device and the ICD. These factors, combined with the urgency and type of surgery and the availability of personnel with expertise in ICDs, will ultimately determine the type and extent of evaluation that is performed at a given institution. Furthermore, in the guidelines published by the American College of Cardiology and the American Heart Association, turning off the shock function in the ICD program (and turning it back on after surgery) is the preferred method of addressing these issues. Therefore, in our patient, we switched off the ICD's shock function and used a bipolar electrocautery system because the distance between the bipolar electronic scalpel and the ICD was short. However, an extracorporeal defibrillator was in stand-

by in case ventricular arrhythmia occurred during surgery. Furthermore, a backup system was established with a clinical engineer present so that the ICD could be reactivated immediately during surgery if necessary.<sup>5</sup>

## Conclusions

We successfully managed anesthesia without the occurrence of potentially lethal arrhythmia in a patient with ARVD and an ICD. During general anesthesia, an adequate amount of analgesia should be administered to maintain an adequate anesthetic depth and to avoid stress and pain. An external defibrillator should also be kept on hand during surgery under anesthesia when an intraoperative ICD is temporarily deactivated for use of electrocautery.

## Conflicts of interest

The authors declare no have conflicts of interest.

## References

1. Corrado D, Link MS, Calkins H. Arrhythmogenic right ventricular cardiomyopathy. *N Engl J Med*. 2017;376:1489–90.
2. Marcus FI, Zareba W, Calkins H, et al. Arrhythmogenic right ventricular cardiomyopathy/dysplasia clinical presentation and diagnostic evaluation: results from the North American Multidisciplinary Study. *Heart Rhythm*. 2009;6:984–92.
3. Gupta R, Tichnell C, Murray B, et al. Comparison of features of fatal versus nonfatal cardiac arrest in patients with arrhythmogenic right ventricular dysplasia/cardiomyopathy. *Am J Cardiol*. 2017;120:111–7.
4. Mu J, Zhang G, Xue D, et al. Sudden cardiac death owing to arrhythmogenic right ventricular cardiomyopathy: two case reports and systematic literature review. *Medicine (Baltimore)*. 2017;96:e8808.
5. Essandoh MK, Mark GE, Aasbo JD, et al. Anesthesia for subcutaneous implantable cardioverter-defibrillator implantation: perspectives from the clinical experience of a U.S. panel of physicians. *Pacing Clin Electrophysiol*. 2018;41:807–16.