

SHORT COMMUNICATION

Anterior scalene plane block at the superior trunk level relieves referred shoulder pain after liver radiofrequency ablation: a technical report



Yin-Tzu Liu^{a,1}, Sheng-Wei Cheng^b, Jin-De Hou^{c,*}, Wei-Chen Chung^a, Hsun-Chung Tsoo^{a,1}, Jui-An Lin^{d,e,f,*}

^a Taipei Medical University, Wan Fang Hospital, Department of Anesthesiology, Taipei, Taiwan

^b Taipei Medical University, Wan Fang Hospital, Department of Internal Medicine, Division of Gastroenterology, Taipei, Taiwan

^c Hualien Armed Forces General Hospital, Division of Anesthesiology, Hualien, Taiwan

^d Taipei Medical University, College of Medicine, School of Medicine, Department of Anesthesiology, Taipei, Taiwan

^e Taipei Medical University, Wan Fang Hospital, Pain Research Center, Taipei, Taiwan

^f Taipei Medical University, Wan Fang Hospital, Centers for Regional Anesthesia and Pain Medicine, Taipei, Taiwan

Received 12 June 2020; accepted 25 October 2020

Available online 17 February 2021

KEYWORDS

Nerve block;
Phrenic nerve;
Pain, referred;
shoulder;
Liver neoplasms;
Radiofrequency
ablation

Abstract We report the first case of using an anterior scalene plane block at the superior trunk level achieving phrenic nerve blockade to treat intolerable referred shoulder pain after liver Radiofrequency Ablation (RFA) of a diaphragm-abutting liver tumor despite prevention with a full-dose non-steroidal anti-inflammatory drug. The anterior scalene plane block rapidly alleviated pain without significant complications.

© 2021 Published by Elsevier Editora Ltda. on behalf of Sociedade Brasileira de Anestesiologia. This is an open access article under the CC BY-NC-ND license (<http://creativecommons.org/licenses/by-nc-nd/4.0/>).

Introduction

Radiofrequency Ablation (RFA) of diaphragm-abutting tumor results in right shoulder pain in some patients. A hypothesis is that an irritation of the phrenic nerve results in neural hypersensitivity of the third and fourth spinal cer-

vical nerves (C3–C4), and subsequently induces a referred shoulder pain.¹ Management typically requires the early institution of parenteral non-steroidal anti-inflammatory drugs, which may eliminate pain in most patients. However, intractable referred shoulder pain that is unresponsive to the above treatment urges the need for further intervention.

Phrenic nerve block may be challenging, considering the potential complications such as incomplete analgesia when blocking it at the level of diaphragm, unwanted local anesthetic spread toward other nerves, and, above all, nerve injury secondary to mechanical needle trauma, pressure-induced neuropraxia as well as intra-fascicular injection.

* Corresponding author.

E-mails: hollowsoul701120@hotmail.com (J-D. Hou), juian.lin@tmu.edu.tw (J-A. Lin).

¹ Y-Z. Liu and H-C. Tsoo contributed equally.

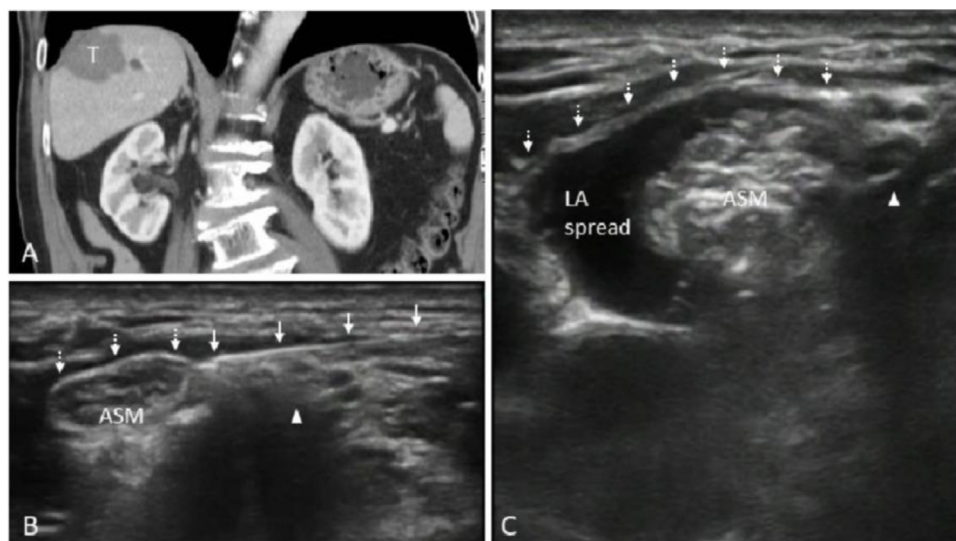


Figure 1 (A) Coronal plane of computed tomography of the diaphragm-abutting tumor. (B) Pre-injection ultrasound image before puncturing the prevertebral fascia. (C) Post-injection ultrasound image with a perimuscular spread beneath the prevertebral fascia. Arrowhead indicates the superior trunk, solid arrow indicates the needle shaft, and broken arrow indicates prevertebral fascia. T, Tumor; ASM, Anterior Scalene Muscle; LA, Local Anesthetic.

Here we proposed an anterior scalene plane approach at superior trunk level under dual guidance (ultrasound and injection pressure) to avoid associated complications as much as possible. Waiver of informed consent has been approved by the TMU-Joint Institutional Review Board (TMU-JIRB n° N201906002).

The technique to manage intractable referred shoulder pain

A 74-year-old man (68 kg) with hepatocellular carcinoma, T2N0M0 (Stage II) and BCLC Stage A previously underwent partial hepatectomy and RFA and received percutaneous ethanol injection. He was otherwise healthy, except for medication-controlled hypertension. This time, he was admitted for a second course of RFA of a recurrent liver tumor approximately 3.5 cm located at segments 7 and 8 adjacent to the liver dome (Fig. 1A).

After being premedicated with intravenous fentanyl (100 mcg) and midazolam (1 mg), 0.15 mL.kg⁻¹ of local anesthetic (0.6% ropivacaine with 1:400000 epinephrine) was injected into the T9, T7, and T5 paravertebral spaces. Owing to its diaphragm-abutting property, parecoxib (40 mg) was intravenously administered to prevent referred shoulder pain caused by diaphragm irritation perioperatively. Sedation was maintained with 1% propofol continuous infusion under bispectral index monitoring. Two cool-tip RFA needles were inserted. Total ablation time was approximately 2-hs, with stable intraoperative blood pressure.

However, after recovery from sedation, he complained of severe pain over the right shoulder region without abdominal discomfort. Cervical phrenic nerve block was planned as preoperative full dose parecoxib failed to prevent referred shoulder pain. The patient was placed in the left lateral decubitus position with scalenus anterior focused sonographically at the superior trunk level to facilitate

ergonomic practice. The needle was meticulously advanced from the lateral to medial direction toward the surface of scalenus anterior with the prevertebral fascia punctured immediately medial to the superior trunk (Fig. 1B). Fascial plane dissection was achieved by half-the-air technique. After negative aspiration, 3 mL of 2% lidocaine, followed by 2 mL of 5% dextrose to empty the dead space of the half-the-air setting, was administered into the subfascial plane with continuous pressure monitoring throughout the injection procedure (Fig. 1C).²

The patient experienced rapid improvement of his shoulder discomfort immediately after local anesthetic injection. Twenty minutes after the injection, complete pain relief was reported by the patient. No respiratory distress was noted during observation, and phrenic nerve blockade was confirmed by a loss of ipsilateral diaphragmatic movement on ultrasound.

Discussion

Regional blocks targeting the phrenic nerve have been previously proposed to treat referred shoulder pain. Local anesthetic infiltration into the periphrenic fat pad at the level of the diaphragm significantly reduces the incidence of shoulder pain, but still experienced by some patients. The reason responsible for incomplete pain relief might be that the phrenic nerve already branches off into various terminals to innervate the widespread end-targets, which, therefore, is not easily covered by local anesthetic infiltration. Thus, to achieve complete analgesia, it would be reasonable to block the phrenic nerve more proximally at the cervical level. Raft et al. demonstrated the potential of erector spinae plane block at T3 and T6 level to alleviate right shoulder pain after laparoscopic cholecystectomy, with unilateral sensory loss to cold over C5–T9 dermatomes after 15 mL 0.5% ropivacaine injection at each level.³ However, its mechanism of action

responsible for shoulder analgesia remains unclear and it is not known whether erector spinae plane block solely at T3 level could provide adequate in-time effect for intractable shoulder pain after liver radiofrequency ablation.

Anterior scalene plane block at the superior trunk level was recommended to block the proximal phrenic nerve without directly getting in touch with the nerve. The phrenic nerve is a predominantly hypoechoic monofascicular structure with a hyperechoic border in the transverse view. The mean diameter of phrenic nerve is only 0.76 mm; therefore, in some cases, tiny nerves cannot be identified using an ultrasound probe with a general resolution.⁴ In our patient, the phrenic nerve could not be traced easily even by dynamic up-and-down scanning. Moreover, phrenic nerve is nearly indistinguishable from the C5 ventral ramus at the level of the cricoid cartilage (mean distance: 1.8 mm), but with additional 3 mm separation between the phrenic nerve and brachial plexus for every cm more caudal in the neck.⁴ Therefore, to avoid phrenic nerve injury secondary to mechanical needle trauma during cervical phrenic nerve block, we punctured the prevertebral fascia immediately medial to the superior trunk where the phrenic nerve already courses over the medial surface of the anterior scalene muscle. The superior trunk level increases the separation substantially between the phrenic nerve and the brachial plexus because the superior trunk is typically found superficial to the C7 nerve root, and the distance from the cricoid cartilage to the C7 transverse process is estimated to be 1.5 and 2.5 cm in the neutral and extended neck positions, respectively.⁵ The transverse scan usually catches the superior trunk at the level caudal to the C7 posterior tubercle. Injection beneath the prevertebral fascia at this level achieves a craniocaudal spread (Fig. 1C) superomedially limited by the fascial attachment of the C3 to C6 anterior tubercles and laterally limited by the outward reflected fascia overlying the superior trunk and subclavian artery in the lower neck. Although whether the phrenic nerve passes onto the surface of prevertebral fascia in the lower neck remains controversial, the proximal portion of the phrenic nerve lies consistently deep to the prevertebral fascia, whose block can be achieved by a cranial spread from injection beneath the prevertebral fascia at the superior trunk level. A perimuscular spread over the anterior scalene plane not only achieved phrenic nerve blockade but also helped minimize unwanted extrafascial spread.

To avoid intrafascicular spread for this invisible tiny string and possible injection pressure-induced neuropraxia, continuous pressure monitoring throughout the injection is

mandatory. Among pressure monitors, the half-the-air setting is recommended for cervical phrenic nerve block. Not only can the half-the-air setting continuously monitor injection pressure² but it also has additional benefits because 5% dextrose as the test volume is useful for fascial plane dissection before drug deposition² to minimize unwanted extra-fascial spread, especially in the complex innervated neck region.

Although our patient experienced complete pain relief after cervical phrenic nerve block, whether a prophylactic phrenic nerve block should be performed as a routine procedure before liver RFA warrants further investigation in terms of a variable incidence of intractable shoulder pain after liver RFA and possible respiratory distress in patients with lung pathology. Furthermore, the optimal drug regimen for anterior scalene plane block needs to be determined.

Conflicts of interest

The authors declare no conflicts of interest.

Acknowledgments

This study was supported by grants from Wan Fang Hospital, Taiwan (108-wf-eva-05), and Hualien Armed Forces General Hospital (805-C108-05).

References

1. Zhang H, Liu X, Jiang H, Liu Z, Zhang XY, Xie HZ. Parecoxib increases muscle pain threshold and relieves shoulder pain after gynecologic laparoscopy: a randomized controlled trial. *J Pain Res.* 2016;9:653–60.
2. Lin JA, Lin KH, Hsu AC, Tai YT. Modified half-the-air technique for continuous pressure monitoring during lumbar plexus block. *Eur J Anaesthesiol.* 2018;35:803–5.
3. Raft J, Chin KJ, Richebe P. Erector spinae plane (ESP) block with a transverse in-plane approach for management of referred shoulder pain after laparoscopic cholecystectomy. *J Clin Anesth.* 2019;55:100–1.
4. Kessler J, Schafhalter-Zoppoth I, Gray AT. An ultrasound study of the phrenic nerve in the posterior cervical triangle: implications for the interscalene brachial plexus block. *Reg Anesth Pain Med.* 2008;33:545–50.
5. An J, Lee YW, Park WY, et al. Variations in the distance between the cricoid cartilage and targets of stellate ganglion block in neutral and extended supine positions: an ultrasonographic evaluation. *J Anesth.* 2016;30:999–1002.