


References

1. Capdeville M, Hargrave J, Patel PA, et al. Contemporary challenges for fellowship training in adult cardiothoracic anesthesiology: perspectives from program directors around the United States. *J Cardiothorac Vasc Anesth.* 2020;34:2047–59.
 2. Erdoes G, Vuylsteke A, Schreiber JU, et al. European Association of Cardiothoracic Anesthesiology (EACTA) Cardiothoracic and Vascular Anesthesia Fellowship Curriculum: First Edition. *J Cardiothorac Vasc Anesth.* 2020;34:1132–41.
 3. Salgado-Filho MF, Morhy SS, Vasconcelos HD, et al. Consenso sobre Ecocardiografia Transesofágica Perioperatória da Sociedade Brasileira de Anestesiologia e do Departamento de Imagem Cardiovascular da Sociedade Brasileira de Cardiologia. *Rev Bras Anesthesiol.* 2018;68:1–32.
 4. Gomes WJ, J Mendonça JT, Domingo, Braile D. Resultados em cirurgia cardiovascular oportunidade para rediscutir o atendimento médico e cardiológico no sistema público de saúde do país. *Rev Bras Cir Cardiovasc.* 2007;22:III–VI.
 5. Lopes MAC, Nascimento BR, Oliveira GMM. Tratamento da Estenose Aórtica do Idoso no Brasil: Até quando podemos esperar? *Arq Bras Cardiol.* 2020;114:313–8.
- Caetano Nigro Neto ^{a,*}, Eric Benedet Lineburger^b, Vinicius Tadeu dos Santos Nascimento^a, Marcello Fonseca Salgado-Filho^{c,d}
- ^a Instituto Dante Pazzanese de Cardiologia, São Paulo, SP, Brazil
^b Hospital São Jose, Criciúma, SC, Brazil
^c Universidade Federal Fluminense, Niterói, RJ, Brazil
^d Santa Casa de Misericórdia, Juiz de Fora, MG, Brazil
- * Corresponding author.
 E-mail: caenigro@uol.com.br (C. Nigro Neto).
- Received 12 October 2020; accepted 14 November 2020
- <https://doi.org/10.1016/j.bjane.2020.11.003>
 0104-0014/ © 2021 Published by Elsevier Editora Ltda. on behalf of Sociedade Brasileira de Anestesiologia. This is an open access article under the CC BY-NC-ND license (<http://creativecommons.org/licenses/by-nc-nd/4.0/>).

Mobile camera as an aid to minimize drug errors



Dear Editor,

Human errors are the most common cause of drug errors.¹ The National Coordinating Council for Medication Error Reporting and Prevention defines medication error is any preventable event that may cause or lead to inappropriate medication use or patient harm while the medication is in the control of the health care professional, patient, or consumer.² Product labeling is one of the several factors that may contribute to such events. A drug label carries information about its composition, recommended mode, and route of administration, manufacturing and expiry date. To

avoid the errors in drug administration, it is strongly recommended that the label on any drug or ampoule or syringe should be carefully read and checked with a second person before a drug is drawn up or injected. Similar packaging and presentation of drugs should also be avoided wherever possible.³

Standard specifications exist for labels for small-volume (100 mL or less) parenteral drug containers. The standard provides recommendations for the color, size, design, general properties and typographical characteristics of the labels. It also states that the font size should be as large as possible to aid readers. A size of 9 points, as measured in 'Times New Roman', not narrowed, with a space between lines of at least 3 mm, is the minimum for the packet leaflet. User testing, meant to test the readability of a specimen

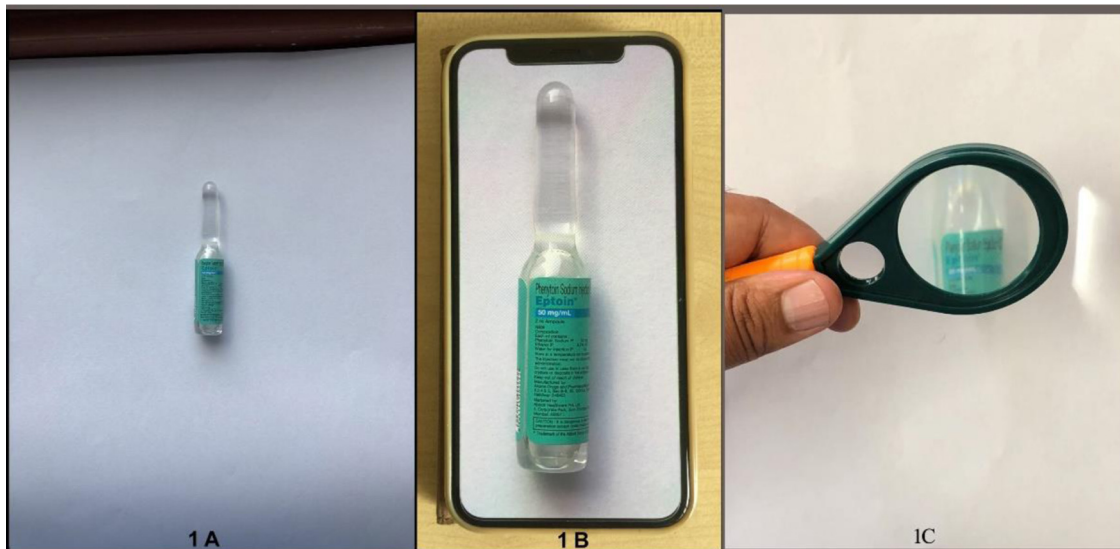

Figure 1 A, Image of ampoule taken while keeping at convenient distance; B, Zoomed mobile image of the same ampoule; C, Ampoule's label as visible through a magnifying glass.

with a group of selected test subjects, is also advocated. The American Society of Anesthesiologists has also amended its statement on creating labels of pharmaceuticals for use in anesthesiology. But we could not find similar literature on ampoules. Several ampoules carry information which is difficult to read by naked eye (Figure 1A). This becomes especially important for ampoules that are looking similar as they carry potential of drug being administered wrongly.⁴ One solution to the problem is to use a magnifying glass to read it but this would necessitate carrying one during practice. Mobile phones are now routinely carried by everyone. Hence an easy and feasible alternate is to have a photograph of the ampoule with the mobile camera and zoom to read it (Figure 1B). The photo could easily be shared with others to have it cross-checked by several persons simultaneously, and any discrepancy in judgment can be resolved. It will also provide complete details at single glance unlike several adjustments required with the magnifying lens (Figure 1C). The image quality will undoubtedly depend on the pixels of camera but it will definitely be an aid to naked eye examination.

Conflicts of interest

The authors declare no conflicts of interest.





Acknowledgement

Authors acknowledge Dr. Anamika Purohit for technical assistance in preparing the manuscript

and Mr. Satyanarayan Tripathi for digital art work.

References

1. Kothari D, Gupta S, Sharma C, Kothari S. Medication error in anaesthesia and critical care: A cause for concern. *Indian J Anaesth.* 2010;54:187–92.
2. The National Coordinating Council for Medication Error Reporting and Prevention. NCC MERP: The First Ten Years 'Defining the Problem and Developing Solutions'; 2005. p. 4.
3. Glavin RJ. Drug errors: consequences, mechanisms, and avoidance. *Br J Anaesth.* 2010;105:76–82.
4. Paliwal B, Purohit A, Sethi P. Apnoea during Spinal Anesthesia: A Medication Error. *Karnataka Anaesth J.* 2016;2:37–8.

Bharat Paliwal , Manoj Kamal , Pradeep Bhatia , Sadik Mohammed 

All India Institute of Medical Sciences, Department of Anesthesiology and Critical Care, Jodhpur, India

* Corresponding author.

E-mail: docbpali@gmail.com (B. Paliwal).

Received 2 October 2020; accepted 29 November 2020

<https://doi.org/10.1016/j.bjane.2020.11.009>

0104-0014/ © 2021 Sociedade Brasileira de Anestesiologia.

Published by Elsevier Editora Ltda. This is an open access article under the CC BY-NC-ND license

(<http://creativecommons.org/licenses/by-nc-nd/4.0/>).

Expanding the horizon of costoclavicular block – shouldering new responsibility!



Dear Editor,

Ultrasound-guided costoclavicular block (CCB) is a variant of infraclavicular brachial plexus block. The advantages of local anesthetic (LA) deposition at costoclavicular space (CCS) include the requirement of low volume as the cords are densely packed, reduce the possibility of pneumothorax and ipsilateral phrenic nerve palsy (PNP).¹ It has been shown to produce effective anesthesia/analgesia in various upper limb surgeries below the shoulder joint. Continuous CCB using a perineural catheter can be used for intraoperative surgical anesthesia and/or postoperative analgesia. Aliste et al. first used CCB for analgesia in arthroscopic shoulder surgery and compared its efficacy with interscalene block (ISB).² CCB provided early-onset equipotent analgesia without any incidence of ipsilateral PNP. The rostral spread of the LA from CCS towards the roots of brachial plexus could block the neural innervation of the shoulder in a retrospective manner without causing PNP.

A recent human cadaveric study also supported these clinical findings.³ Ultrasound-guided injection of 20 mL dye (0.1% methylene blue) in the CCS was found to spread towards cephalad part of brachial plexus. It stained all trunks and cords of the brachial plexus, including the

suprascapular nerve, while sparing the phrenic nerve. The reported incidence of PNP in clinical settings following the CCB is low but variable. Ipsilateral PNP was observed in 0% or 5% with 20 ml and 8.9% with 35 ml of LA following ultrasound-guided CCB in various clinical settings.^{1,2,4} Bilateral use of CCB with 15 ml of LA for each side was also reported without any clinical or sonographic evidence of PNP.¹ We have been using CCB in our daily practice since its first description in the literature and observed a relatively very low incidence of clinically significant PNP. Still, a greater number of clinical trials on a large number of patients is the need of the hour to push its boundaries for shoulder anesthesia/analgesia.

The understanding of dermatomal, myotomal, and osteotomal innervations are essential to provide procedure-specific optimal anesthesia or analgesia of the shoulder area. Suprascapular and axillary nerves supply a significant part of the osteotome and myotome around the shoulder and proximal humerus. Subscapular, medial pectoral, lateral pectoral, musculocutaneous, thoracodorsal, and radial nerves also contribute to supply myotomes. Although ISB is considered as the gold standard in shoulder analgesia, the inherent risks of ipsilateral PNP limit its use in patients with pre-existing pulmonary compromise.⁵ Several modifications of ISB or other diaphragm-sparing nerve blocks have been investigated for shoulder surgeries but failed to achieve either surgical anaesthesia or 0% incidence of PNP. The various innervations of shoulder joint covered and spared in ISB, selective superior trunk block (STB), and CCB are mentioned in Table 1. It is now evident from anatomical and