



CASE REPORTS

Circumpsoas block – an anterior myofascial plane block for lumbar plexus elements: case report[☆]

Sandeep Diwan^a, Abhijit Nair^{b,*}, Nitin Gawai^a, Dipal Shah^c, Parag Sancheti^d

^a Sancheti Hospital, Department of Anesthesiology, Pune, India

^b Department of Anesthesiology, Ibra Hospital, Ibra, Oman

^c Sancheti Hospital, Department of Radiodiagnosis, Pune, India

^d Sancheti Hospital, Department of Orthopedics, Pune, India

Received 16 August 2020; accepted 2 April 2021

Available online 29 April 2021

KEYWORDS

Femur;
Intertrochanteric fracture;
Ultrasonography;
Regional Anesthesia;
Acute pain;
Postoperative pai

Abstract In an attempt to improvise the analgesia in patients with femoral fractures, we aimed at depositing local anesthetic deep to anterior psoas fascia (APf) under ultrasound (US) guidance to block lumbar plexus elements which emerge lateral, anterior, and medial to the psoas major muscle. We termed this as circumpsoas block (CPB). Clinical and computed tomography contrast studies revealed that a continuous CPB infusion with a catheter provided a reliable block of the lumbar plexus elements. No adverse were events noted. We conclude that US guided CPB is a reliable technique for managing postoperative pain after surgery of femur fractures.

© 2021 Sociedade Brasileira de Anestesiologia. Published by Elsevier Editora Ltda. This is an open access article under the CC BY-NC-ND license (<http://creativecommons.org/licenses/by-nc-nd/4.0/>).

Introduction

Anterior and posterior approach to lumbar plexus block (LPB) is implemented for unilateral postoperative analgesia after surgery for fractures of proximal, mid, and distal femur. Clinical and radiological studies of the infra-inguinal fascia iliaca compartment block (FICB) failed to exhibit a

reliable blockade of lumbar plexus elements.^{1,2} To overcome the shortcomings of infrainguinal FICB, i.e., failure to block the obturator nerve, very high volumes of local anesthetic (LA) achieved blockade of all three nerves with the suprainguinal FICB.^{3,4}

Anatomically, the three target nerves (femoral nerve, lateral femoral cutaneous nerve (LFCN), obturator nerve) emerge lateral and medial to psoas major muscle (Pma) engulfed by the psoas fascia.⁵ In an attempt to improvise the analgesia in patients with femur fractures, we aimed at depositing LA through a catheter positioned deep to anterior psoas fascia (APf) under ultrasound (US) guidance to block lumbar plexus elements which emerge lateral, anterior, and medial to the psoas major muscle. We termed this as cir-

[☆] The research was presented as a free paper at 38th annual European Society of Regional Anesthesia Congress, 2019 held at Bilbao, Spain.

* Corresponding author.

E-mail: abhijitnair95@gmail.com (A. Nair).

Table 1 Demographic details including ASA-PS, side of surgery.

S.no.	Variables
Age (years)	49.5 (40.25–56)
Gender (M/F)	19/13
S.no.	Variables
Weight in kg (expressed as median with interquartile range)	63.50 (59–68.75)
ASA-PS (I/II)	14/18
Side of surgery (right/left)	18/14

cumpsoas block (CPB). The spread of LA in the vicinity of the target nerves was confirmed with computed tomography (CT) contrast studies.

The purpose of this series is to demonstrate the technical feasibility and analgesic efficacy of US-guided CPB.

Case series

Institutional Ethics Committee approved the study and informed consent was obtained from all patients. The study recruited 32 American Society of Anesthesiologists (ASA) physical status I–II patients (19 male, 13 female). Demographics is explained in Table 1. The patients with isolated proximal femoral mid-shaft and distal femur fractures were

considered appropriate for inclusion in the study. Patients with a history of allergy to LA drugs, localized skin infection, underlying coagulopathy, or body mass index (BMI) greater than 30 kg.m⁻² were excluded from the study. Routine investigations were performed in all patients (complete blood count, serum creatinine, coagulation profile, viral screening). Appropriate gauge intravenous (IV) access was secured and vitals (electrocardiogram, heart rate, oxygen saturation, and noninvasive blood pressure) were monitored. A standard general anesthesia (GA) induction (midazolam 0.03 mg.kg⁻¹, fentanyl 1 µg.kg⁻¹, propofol 2 mg.kg⁻¹, cisatracurium 0.2 mg.kg⁻¹) was implemented and the airway was secured with an appropriately sized endotracheal tube. GA was maintained with oxygen: air (fresh gas flow of 1 L) and sevoflurane over volume-controlled ventilation with monitoring of end-tidal carbon dioxide. Intraoperatively 0.5 µg.kg⁻¹ fentanyl was the analgesic to be administered if heart rate and blood pressure increased by 20% from baseline and was considered as an inadequate block. The US-guided block was performed after the induction of GA.

Block technique

Under due asepsis, a linear array high-frequency ultrasound (US) probe with 13–6 Mhz (Sonosite: Model, M-Turbo, Fujifilm Sonosite Inc, USA) was deployed below the inguinal ligament

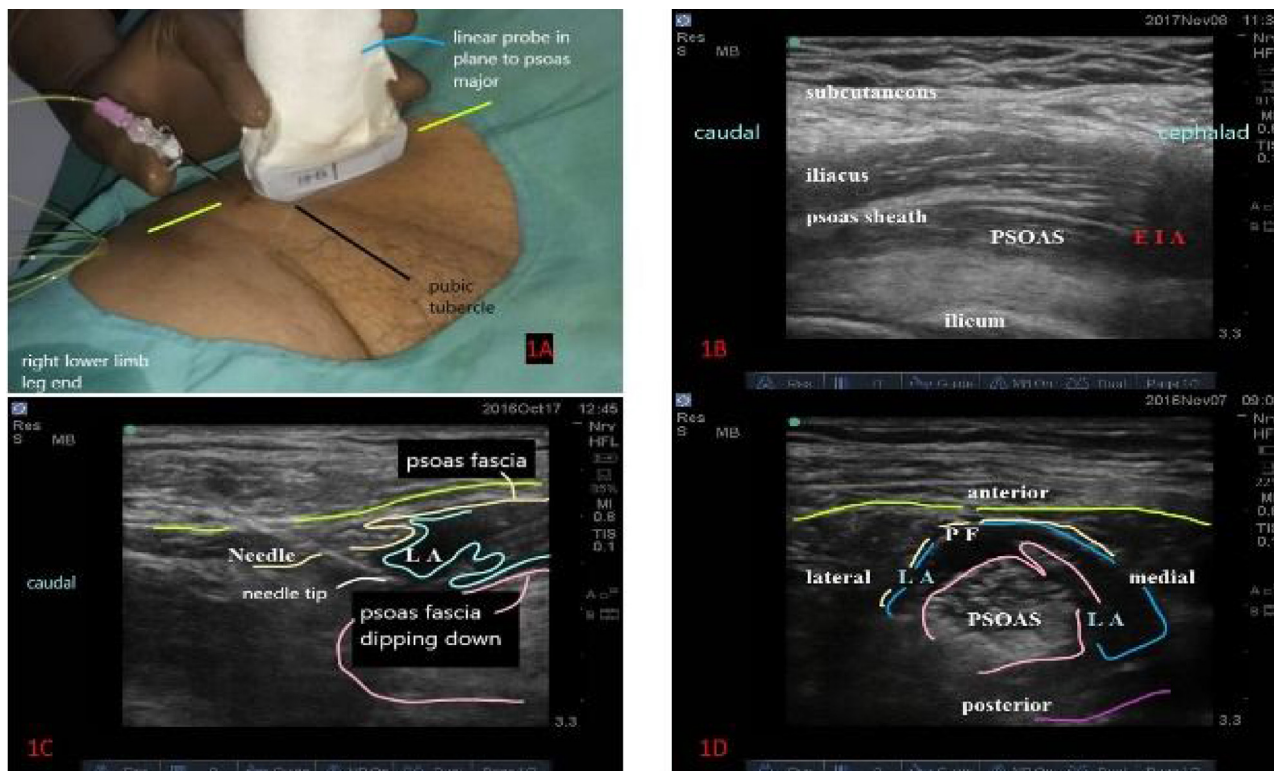


Figure 1 A, Placement of ultrasound probe immediately above the inguinal ligament with needle and catheter introduced in-plane; B, Longitudinal ultrasound image depicting the sonoanatomy for CPB, from below upwards are the Pma with the psoas sheath and the iliacus; C, Longitudinal ultrasound image depicting the needle insertion beneath the APf (anterior psoas fascia) in light yellow. LA injection (light blue) lifts the APf and depresses the Pma (light pink); D, Axial view depicting the spread of LA (light blue) around the Pma (light pink) lifting the APf (light yellow).

Table 2 (Continued)

Pathway			Spread in 10 patients in percentage				
---------	--	--	-------------------------------------	--	--	--	--

Table showing spread of contrast in various pathways/ dermatomes.

Case no.	Catheter position	CT views	Pudendal	L3	L4	L5	S1
1	Medial to Pma	A	Red	Red	Blue	Blue	Blue
		S	Red	Red	Blue	Blue	Blue
		C	Red	Red	Blue	Blue	Blue
2	Medial to Pma	A	Blue	Red	Red	Blue	Red
		S	White	Red	Blue	Blue	Blue
		C	White	Red	Red	Red	Red
3	Between Pma and FI	A	Red	Red	Red	Blue	Red
		S	Red	Red	Red	Red	Red
		C	Red	Red	Red	Red	Red
4	Between Pma and FI	A	Red	Red	Blue	Blue	Red
		S	Red	Red	Blue	Blue	Red
		C	Red	Red	Blue	Blue	Red
5	Superior to Pma	A	Red	Red	Blue	Blue	Red
		S	Red	Red	Blue	Blue	Red
		C	Red	Red	Red	Red	Red
6	Superior to Pma	A	White	White	White	White	White
		S	White	White	White	White	White
		C	Red	Red	Blue	Blue	Blue
7	Superior to Pma	A	Red	Red	Blue	Blue	Red
		S	Red	Red	Blue	Blue	Red
		C	Red	Red	Red	Red	Red
8	Medial to Pma	A	Red	Red	Red	Red	Red
		S	Red	Red	Red	Red	Red
		C	Red	Red	Red	Red	Red
9	Superior to Pma	A	Red	Red	Red	Red	Red

Blue box, definite spread of contrast; red box, no spread of contrast, white/ uncoloured box: partial spread of contrast. A- axial section, S-sagittal section, C- coronal section, Pma- psoas major muscle.

and the psoas tendon, iliacus muscle and fascia, femoral nerve, and femoral artery were identified in a transverse scan. The probe was rotated in a longitudinal axis aligned with the psoas tendon and was shifted cephalad to identify the supra-inguinal part of Pma. The final probe position in the longitudinal axis (Fig. 1A) was immediately above the inguinal ligament and the US image demonstrated the sheath over the Pma (Fig. 1B). The tip of 18G Tuohy's needle (B. Braun Medical Inc. USA.) was positioned (Fig. 1B) deep to the APf and on the anterior aspect of Pma. During the entire procedure, the needle tip was visualized in real-time as it pierced the APf. With the needle tip deep to APf, hydrodissection was performed injecting 3 ml of 0.9% saline. After confirming the correct placement of needle tip, 20 ml of 0.2% ropivacaine was injected through the needle, and a catheter (20G, Braun Medical Inc. USA.) was inserted in the plane created between the APf and Pma, to a distance of 5–6 cm (Fig. 1B). Following a negative aspiration for blood, 10 ml 0.2% ropivacaine was injected through the catheter. The injected LA lifted the psoas sheath and depressed the Pma as the LA spread could be appreciated cephalad below the psoas sheath in the longitudinal scan (Fig. 1C). At this level of injection, the probe was rotated in a transverse scan and the LA spread around the muscle in lateral, anterior, and medial directions were confirmed (Fig. 1D). Intraoperative heart rate, blood pressure and oxygen saturation were monitored throughout the procedure. The surgical duration was 1.5–2 hours.

Neuromuscular blockade was reversed with neostigmine (0.1 mg.kg⁻¹), and glycopyrrolate (0.01 mg.kg⁻¹) and the trachea were extubated. Patients were shifted to a high

dependency unit for monitoring of vital parameters (electrocardiogram, blood pressure, oxygen saturation). A visual analog scale (VAS) was used to monitor postoperative pain. The time to first rescue analgesia (TTFA) and 24-hours rescue analgesia requirement was noted for all patients. Postoperatively, 0.1% ropivacaine was infused at a rate of 8 mL.h⁻¹ through an infusion pump (B Braun Perfusor® Space pump). Paracetamol 1 g IV was infused 30 minutes before the closure of the surgical wound, and every 8 hours for the next 48 hours. Diclofenac 75 mg IV was planned as rescue analgesia if the VAS score was more than 4. The extent of sensory block achieved was assessed at the end of the surgery once the patient was wide awake.

All patients were hemodynamically stable throughout the surgery and perioperative period. Mean VAS score at 0, 1, 3, 6, 12, 18, and 24 hours postoperatively were 1.21, 1.4, 1.71, 1.96, 2.21, 2.28, and 2.5, respectively. Intraoperatively, no patient required additional IV fentanyl boluses. None of the patients required rescue analgesic in first 24 hours. There were no adverse events noted in any patient. The sensory block achieved was assessed postoperatively and involved the LFCN and the FN.

On the second postoperative day, after obtaining informed consent, 10 patients underwent a CT-contrast study (5 ml Omnipaque – 300 mg i/ml – Iohexol, a non-ionic, water-soluble radiographic contrast medium in 25 ml of normal saline) to identify the spread of LA through the catheter in psoas sheath. The infusion pump was turned off 30 minutes before injection. The charges for imaging and contrast used was waived off by the hospital. The images were reported in collaboration with a consultant radiologist.

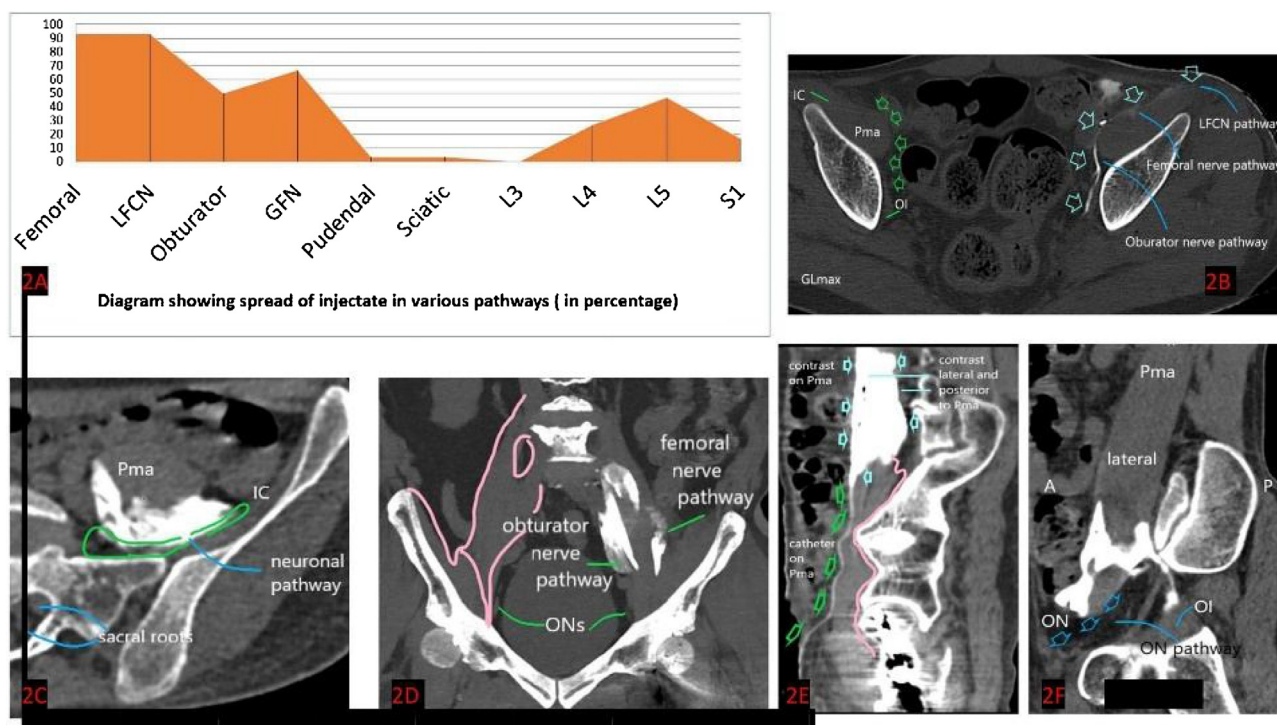


Figure 2 A, CT contrast spread analysis revealing the spread along the femoral, lateral femoral cutaneous nerve (LFCN), Obturator, genitofemoral (GFN), pudendal, sciatic, the L3, L4, L5, and S1 extraforaminal root level; B, Axial view: contrast spread along the anterior surface of Pma, femoral, LFCN, and obturator pathway. It spreads as far as the upper portion of the obturator internus (OI). Pma, psoas major; GL max-gluteus maximus; C, Axial view: contrast spreads in the posterior surface of the Pma and close to the origin of the 5th lumbar nerve root, in the neuronal pathway. Pma, psoas major; IC, Iliacus; D, Contrast spread along the medial and lateral borders of Pma that is along the obturator and femoral pathways. Obturator nerve (ON) can be visualized bilaterally at the pelvic brim; E, Catheter extends from the caudal portion of the Pma until it reaches the level of sacroiliac joint at which point it merges with contrast that spreads cephalad on the anterior border, lateral surface, and posterior border of Pma; F, The anterior and posterior surfaces of the Pma are surrounded by contrast in its lower portion. Contrast trickles from the posterior surface and spills in the obturator (ON) pathway onto the superior surface of obturator internus (OI).

Representative CT-contrast images from 10 patients demonstrated the contrast spread across various neural pathways which we term as femoral, LFCN, and obturator pathways (Table 2). The contrast spread along femoral and LFCN pathways was 93.33% each and obturator pathway it was 53.33% (Fig. 2A). The spread of contrast was observed at L4, L5, and S1 in 26.66%, 46.66%, and 16.66% (Fig. 2A).

The contrast was seen spreading across the femoral, LFCN, and obturator pathways anterior to Pma (Fig. 2B and posterior to Pma (Fig. 2C – axial at the sacro-iliac joint). In the coronal section contrast distribution in along the femoral and the obturator pathway is depicted (Fig. 2D). In the sagittal section (Fig. 2E), contrast exiting the catheter surrounded the anterior, lateral, and posterior of Pma. Contrast occupied the obturator pathway as it transgressed posteriorly from the posterior surface of Pma and was seen on the upper surface of obturator internus muscle (Fig. 2F).

Discussion

Our case series of US-guided CPB demonstrates its safety and efficacy in terms of no additional intraoperative analgesic requirement and time to the first analgesic at a mean of 15.6 hours. None of the patients required rescue analgesics

in the form of diclofenac 75 mg IV. Postoperative delineation was consistent with the sensory blockade of femoral and lateral femoral cutaneous nerve (LFCN). CT contrast studies revealed the spread of solution across the LFCN and femoral pathways in 93.33% and 53.33% in the obturator pathway. Anatomically and radiographically, the US-guided CPB appears an alternative to the anterior approach to lumbar plexus components.

Clinical studies claim reduction in morphine requirements with 2.6 mg.kg⁻¹ (high concentration) of 0.5% ropivacaine in a longitudinal supra-inguinal FICB.³ The same group of researchers in another study (high volume – 40 ml 0.5% ropivacaine) demonstrated more than 80% obturator nerve blockade with US-guided suprainguinal FICB through gadolinium- based magnetic resonance imaging.⁴

In CPB, LA injections deep to the APf and superficial to the Pma, targets the terminal lumbar plexus nerves in the myofascial plane, before the exit of the LFCN, femoral, genitofemoral, and the obturator nerves in the natural bilateral psoas channels. By further positioning the catheter in the myofascial plane deep to APf and superficially on the anterior surface of Pma, the volume and concentration of LA required could be reduced, thus decreasing the fear of local myotoxicity and neural injuries are remote with CPB. Con-

tinuous uninterrupted visualization of the needle tip under US guidance is essential to avoid vascular and bowel injuries.

Although simple with the US, the block has its limitations. In morbidly obese patients, the structures are difficult to visualize. The block does not appear to provide surgical anesthesia and is indicated for postoperative analgesia. Although it is a myofascial plane block, we do not suggest this block in coagulopathic patients. Blocks were performed after GA and immediate sensory delineation was not done. Obturator nerve block was not clinically evaluated.

Through our series, we propose a new approach that can be considered as a safe alternative to block all nerves emerging from the lumbar plexus. Our initial clinical description and its evaluation using contrast images demonstrate blockade of all four major nerves which exits the medial and lateral borders of psoas muscle at its medial third.

Conflicts of interest

The authors declare no conflicts of interest.

References

1. Capdevila X, Biboulet P, Bouregba M, et al. Comparison of the three-in-one and fascia iliaca compartment blocks in adults: clinical and radiographic analysis. *Anesth Analg.* 1998;86:1039–44.
2. Desmet M, Balocco AL, Van Belleghem V. Fascia iliaca compartment blocks: different techniques and review of the literature. *Best Pract Res Clin Anaesthesiol.* 2019;33:57–66.
3. Desmet M, Vermeylen K, Van Herreweghe I, et al. A longitudinal supra-inguinal fascia iliaca compartment block reduces morphine consumption after total hip arthroplasty. *Reg Anesth Pain Med.* 2017;42:327–33.
4. Vermeylen K, Desmet M, Leunen I, et al. Supra-inguinal injection for fascia iliaca compartment block results in more consistent spread towards the lumbar plexus than an infra-inguinal injection: a volunteer study. *Reg Anesth Pain Med.* 2019, <http://dx.doi.org/10.1136/rapm-2018-100092>. Ahead of print.
5. Kirchmair L, Lirk P, Colvin J, et al. Lumbar plexus and psoas major muscle: not always as expected. *Reg Anesth Pain Med.* 2008;33:109–14.