

CASE REPORT

Continuous erector spinae plane block for analgesia and better pulmonary functions in patients with multiple rib fractures: a prospective descriptive study



Rashmi Syal *, Sadik Mohammed, Rakesh Kumar, Nidhi Jain, Pradeep Bhatia

All India Institute of Medical Sciences, Department of Anesthesiology and Critical Care, Jodhpur, India

Received 8 January 2021; accepted 5 September 2021

Available online 5 October 2021

KEYWORDS

Rib Fractures;
Erector Spinae Plane
Block;
Pulmonary functions;
Analgesia;
Visual Analogous
Scale (VAS)

Abstract

Background: The present study explored the role of continuous erector spinae plane (ESP) block for analgesia as well as its impact on pulmonary functions in patients with multiple rib fractures.

Methods: Ten patients with multiple rib fractures were enrolled after getting informed and written consent. Ultrasound-guided ESP block was performed at the level midway between the fractured ribs followed by the insertion of the catheter. Pre- and post-block VAS score, hemodynamics, respiratory rate (RR), peripheral oxygen saturation (SpO₂), inspiratory capacity (IC), blood gases (PaO₂ and PCO₂), and complications were compared.

Results: Pain scores at rest as well as on movement showed a significant reduction from 5.9 and 7.5 pre block to 1.6 and 2.5 respectively at 96 hours ($p < 0.0001$). Similarly, RR, SpO₂, IC, and PaO₂ were significantly better after the block placement ($p < 0.001$).

Conclusion: Continuous ESP block provide adequate analgesia with better respiratory functions in patients with multiple rib fractures.

© 2021 Published by Elsevier Editora Ltda. on behalf of Sociedade Brasileira de Anestesiologia. This is an open access article under the CC BY-NC-ND license (<http://creativecommons.org/licenses/by-nc-nd/4.0/>).

Introduction

Rib fractures contribute to the significant morbidity in trauma victims which include pain, hemotho-

rax/pneumothorax, pneumonia, etc. Moderate to severe pain that follows multiple fractured ribs limit the patient's ability to take a deep breath, cough-out secretions, and decrease their mobility. In contrast to the fractures of other bones, rib fractures usually do not require surgical intervention; the conservative management includes adequate analgesia thereby preventing respiratory complications.

* Corresponding author.

E-mail: rashmisyal2006@gmail.com (R. Syal).

Regional anesthetic techniques including thoracic epidural analgesia (TEA) and thoracic paravertebral block (TPVB) have been performed to provide analgesia in patients with multiple rib fractures. Although both techniques provide adequate pain control, their associated complications are a limiting factor. Recently introduced ultrasound (US) guided erector spinae plane (ESP) block has been used for thoracic neuropathic pain, acute post-surgical pain in breast and cardiac surgeries and multiple rib fractures.¹⁻³ In this case series, we evaluated the analgesic efficacy of ESP block as well as its impact on pulmonary functions in patients with multiple rib fractures.

Methods

After getting approval from the institute's ethical committee (AIIMS/IEC/2019/845) and written informed consent, a total of 10 patients with American Society of Anesthesiologists (ASA) physical status I to IV, aged between 18 to 70 years, having multiple rib fractures (2 or more ribs) with visual analogous scale (VAS) more than 4 were included in this study. Patient refusal, requirement of mechanical ventilator support, bilateral rib fractures, and infection at the block site were the exclusion criteria. Patients were explained about reporting pain on the VAS scale and were trained regarding the use of Coach 2 incentive spirometer (Smiths Medical) to assess the bedside inspiratory capacity (IC). Baseline hemodynamic parameters [heart rate (HR), systolic blood pressure (SBP), and diastolic blood pressure (DBP)], peripheral oxygen saturation (SpO₂), respiratory rate (RR), VAS score, IC, and arterial blood gas (ABG) values were recorded before the placement of the block. Under all aseptic precautions, with the help of an ultrasound machine (LOGIQe, GE Healthcare, Chicago, United States) and a high frequency (8–15 MHz) linear probe, the ESP block was performed on the affected side at the level midway between the fractured ribs. After skin infiltration with 2% xylocaine, the hyperechoic shadow of the transverse process was appreciated in the paramedian sagittal view. An 18G 90-mm insulated echogenic needle (Contiplex, B Braun, Bethlehem, PA, USA) was advanced using the in-plane technique until the tip crosses the erector spinae muscle which was confirmed by hydro-dissection with 1–2 mL of normal saline. All patients received 0.3 mL.kg⁻¹ of 0.2% ropivacaine as a bolus followed by catheter (20G) insertion 3 cm distal to the needle tip. Subcutaneous tunnelling of the catheter at the insertion site was done and a transparent adhesive dressing was applied to secure the catheter and the catheter insertion site was inspected daily to find out any complication. Infusion of 0.2% ropivacaine (0.1 mL.kg⁻¹.h⁻¹) was continued throughout the study period. Rescue analgesia in the form of tramadol 2 mg.kg⁻¹ was given on recording of VAS ≥ 4 or patient demand. Post-block hemodynamics (at every 10 minutes till 60 min, at 6 hours and then at every 12 hours till 96 hours), VAS (at 60 min, at 6 hours, 12 hours and then at every 12 hours till 96 hours), IC and ABG (at every 24 hours) and occurrence of side effects/complications were recorded. The primary outcome of our study was to assess analgesia using the VAS score. The secondary outcomes were to assess IC, ABG, amount of rescue analgesia required, and incidence of any procedure-related complications. For sta-

Table 1 Demographic profile (age, weight, and ASA status), number of fractured ribs, and level at which the block was performed.

Parameters	Mean ± SD/ Median (IQR)
Age (years)	53.4 ± 12.7
Weight (kg)	63.2 ± 10.11
ASA physical status (I/II/III)	10/0/0
Number of fractured ribs	5 (3, 7)
Thoracic level at which block was performed	5.5 (4, 7)

tistical analysis, categorical measurements were presented in numbers or ratio and quantitative variables were presented as median (range) or mean (SD). Repeated measure ANOVA and Friedman's test was used to compare pre and post quantitative and qualitative data.

Results

Out of sixteen patients screened, six were excluded (4 not meeting the inclusion criteria and 2 refused to participate). **Table 1** represents the demographic profile (age, weight, and ASA status), number of fractured ribs, and level at which block was performed. The mean pain scores at rest as well as on movement showed a significant reduction from 5.9 ± 1.19 and 7.5 ± 1.26 pre block to 1.3 ± 0.67 and 2.5 ± 0.91 respectively at 96 hours ($p < 0.0001$) (**Fig. 1**). Similarly, RR, SpO₂, IC, and PaO₂ were significantly better after the block placement ($p < 0.001$) (**Table 2**). The hemodynamic variables (**Fig. 2**) and PCO₂ (**Table 2**) did not show any significant change ($p > 0.05$). Four patients required a total of five doses of rescue analgesia (two on day 1, two on day 2, and one on day 3). No complications were reported during block placement and observation period.

Discussion

In the present study, we found that ESP block could provide significant improvement in pain score and the continuous catheter technique ensured adequate analgesia for a prolonged period. Also, adequate analgesia translated into better pulmonary rehabilitation and therefore improved respiratory function.

Mortality from rib fractures has been reported to be as high as 33% and contributing factors are disruption of respiratory mechanics and pain.⁴ For patients with pre-existing respiratory comorbidities or opioid sensitivity, regional anesthesia is often lifesaving. Thoracic epidural analgesia (TEA) & paravertebral block (PVB) have been used extensively in patients with multiple rib fractures. However, the associated injuries such as spinal cord injuries, vertebral fractures, unstable pelvis, severe head injury, coagulopathies, and hemodynamic instability limit the use of these blocks. Also, few studies suggest that TEA increases the length of hospital stay in these patients.⁵

ESP block is an interfascial block, simple to perform, and is relatively safer as the target plane is superficial to the transverse process and the needle tip remains distant from pleura, major vessels and discrete nerves.^{1,6} Local anes-

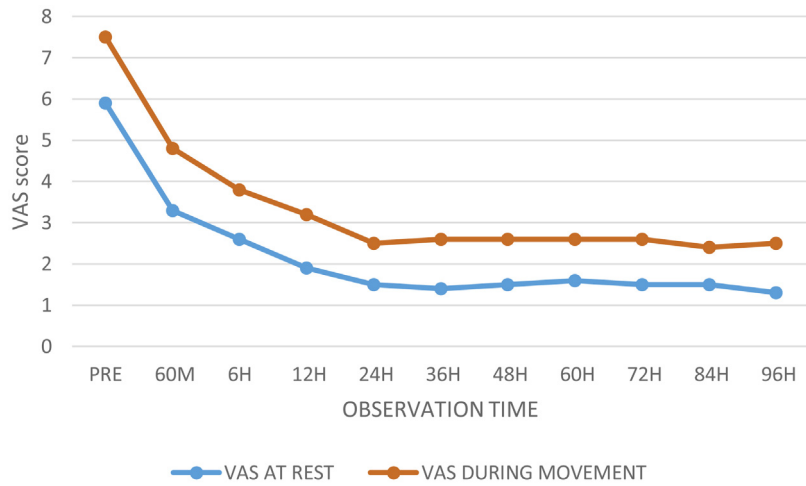


Figure 1 Baseline VAS score and VAS recorded at the various time point of observation at rest and during movement.

Table 2 Respiratory rate, peripheral oxygen saturation, inspiratory capacity, and blood gas values recorded at baseline and at the various time points of observation. Values are presented as [mean ± SD].

Parameters	Pre-block	At 60 min	At Day 2	At Day 3	At Day 4	p-value
Respiratory Rate (per min)	23 ± 8.80	18.2 ± 5.16	17.9 ± 3.54	16.5 ± 2.65	16.9 ± 2.132	0.0001
Peripheral Oxygen Saturation (%)	94	96	96	96	98	< 0.0001
Inspiratory Capacity (mL)	437.5 ± 164.68	565 ± 213.5	710 ± 246.98	875 ± 411.8	917.5 ± 427.86	< 0.0001
PaO2 (mm Hg)	64.25 ± 8.452	67.81 ± 8.165	68.86 ± 10.038	70.96 ± 8.951	72.9 ± 9.129	< 0.0001
PCO2 (mm Hg)	32.6 ± 8.45	33.07 ± 6.46	33.18 ± 2.99	33.52 ± 1.33	33.96 ± 2.708	0.9648

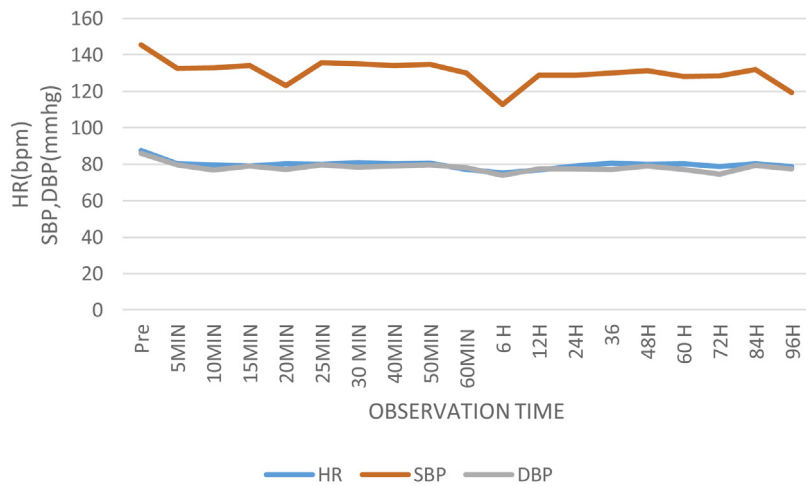


Figure 2 Baseline hemodynamic parameters (HR, SBP, and DBP) and hemodynamic parameters recorded at various time points of observation.

thetic (LA) administered diffuses to the ventral and dorsal rami of spinal nerves, as well as to the paravertebral and the epidural space to provide sensory blockade of multiple dermatomes.⁶ Based on earlier studies^{2,3} and case reports of erector spinae block, we assumed that the dose and concentration that was used for analgesia in most of the thoracic paravertebral blocks⁷ (bolus of 0.3 mL.kg⁻¹ of 0.2% ropivacaine) followed by infusion of 0.1 mL.kg⁻¹.h⁻¹.h⁻¹ is sufficient for analgesia in most of the patients posted for ESP block and this will also help in easy dose calculation.

In a similar retrospective cohort study, authors found that IC was nearly doubled from baseline and this effect was maintained over 72 hours. Maximum pain scores were statistically significantly reduced however, the reduction in 12-h opioid consumption did not reach the significance limit.² This difference might be explained by the fact that in their study only 77% of patients received continuous block while the remaining received a single-injection technique. Furthermore, the range of duration for which the catheter remained sited was 0.6–9.3 days.

The extent of dermatomal spread with erector spinae block is variable. Results of a cadaveric study showed that the injected dye spread in erector spinae fascial plane was found to be two to four spinal nerve levels in the majority of specimen,⁶ while as per one cadaveric study, drug given at T5 level could spread between C7 and T8.¹ This variable cephalo-caudal extent may be one possible reason for the dermatomal sparing and need of rescue analgesia in three of our patients with multiple fractures and extensive injuries. In these patients, two level blocks can be more effective, although this has yet to be proven.⁸ In one of our patients, catheter got blocked on day 2, due to which 1 dose of rescue analgesia was needed and then catheter was reinserted after taking all aseptic precautions.

Few case reports have also showed the role of continuous ESP block for pain relief in trauma patients with multiple rib fractures needing ICU care.^{9,10}

Conclusion

To conclude, ESP block provided an improvement in pain scores and respiratory parameters in patients suffering from traumatic rib fractures. It may represent an attractive and viable alternative for such patients. Because of the inherent biases of prospective single arm descriptive study, further studies with adequate sample size and design are required to reciprocate the findings of our study.

Conflicts of interest

The authors declare no conflicts of interest.

References

1. Forero M, Adhikary SD, Lopez H, et al. The erector spinae plane block: A novel analgesic technique in thoracic neuropathic pain. *Reg Anesth Pain Med.* 2016;41:621–7.
2. Adhikary SD, Liu WM, Fuller E, et al. The effect of erector spinae plane block on respiratory and analgesic outcomes in multiple rib fractures: a retrospective cohort study. *Anaesthesia.* 2019;74:585–93.
3. Nagaraja PS, Ragavendran S, Singh NG, et al. Comparison of continuous thoracic epidural analgesia with bilateral erector spinae plane block for perioperative pain management in cardiac surgery. *Ann Card Anaesth.* 2018;21:323–7.
4. Pressley C, Fry W, Philp A, et al. Predicting the outcome of patients with chest wall injury. *Am J Surg.* 2012;204:910–4.
5. McKendry KM, Lee LF, Boulva K, et al. Epidural analgesia for traumatic rib fractures is associated with worse outcomes: a matched analysis. *J Surg Res.* 2017;214:117–23.
6. Yang HM, Choi YJ, Kwon HJ, et al. Comparison of injectate spread and nerve involvement between retrolaminar and erector spinae plane blocks in the thoracic region: a cadaveric study. *Anaesthesia.* 2018;73:244–50.
7. Batra RK, Krishnan K, Agarwal A. Paravertebral block. *J Anaesthesiol Clin Pharmacol.* 2011;27:5–11.
8. Tulgar S, Selvi O, Ozer Z. Clinical experience of ultrasound guided single and bi-level erector spinae plane block for post-operative analgesia in patients undergoing thoracotomy. *J Clin Anesth.* 2018;50:22–3.
9. Gursoy C, Kuscu Y, Demirbilek SG. Pain Management for Traumatic Rib Fractures with ESP Block in ICU. *J Coll Physicians Surg Pak.* 2020;30:318–20.
10. Nandhakumar A, Nair A, Bharath VK, et al. Erector spinae plane block may aid weaning from mechanical ventilation in patients with multiple rib fractures: Case report of two cases. *Indian J Clin Anesth.* 2018;62:139–41.