



REVISTA BRASILEIRA DE ANESTESIOLOGIA

Publicação Oficial da Sociedade Brasileira de Anestesiologia
www.sba.com.br



LETTERS TO THE EDITOR

Sedation with dexmedetomidine on Klippel Feil Syndrome infant patient



Sedação com dexmedetomidina em paciente pediátrico com síndrome de Klippel-Feil

Dear Editor,

Klippel Feil Syndrome (KFS) is a congenital malformation which has a failure of segmentation of cervical somites in the 8th weeks of gestation and fusion at least two cervical segments.¹ It is described as the triad of short neck, low posterior hairline and decreased range of neck motions.² Especially decreased range of neck motions lead many anesthesiologists to difficult airway management. Dexmedetomidine is used for sedation especially without respiratory depression and for use in very early age group pediatric patients was not observed in reported cases.³ In this case; we aimed to present successful sedation by dexmedetomidine to infant patient who is 65 days aged, diagnosed KFS, limited neck motions and known difficult airway.

Infant patient, who is 65 days aged, 4 kg weight, 81 cm height and diagnosed KFS, was scheduled for a neck MRI. On evaluation of patient; short neck, low posterior hairline, thorax deformity and floating finger was found. The mouth opening of patient was normal but the extension of neck was particularly restricted. Systemic examination revealed no other abnormalities. The chest X-ray showed hypoplastic ribs. In medical history of patient; there was

intermittent respiratory distress. The patient was taken to the anesthetic preparation room. Standard monitorization (electrocardiography, heart rate, oxygen saturation) were performed and intravenous (IV) line was obtained. After preoxygenation for 5 min by facemask, dexmedetomidine infusion was administered by IV route as bolus of 0.5 mcg.kg⁻¹ dose for 10 min. Monitorization data and Ramsey Sedation Score of the patient were recorded at intervals of 5 min. Ear plugs was inserted into patient for protection of loud sounds in MRI room. After bolus administration, dexmedetomidine infusion was continued for maintenance dose as 0.6 mg.kg⁻¹.h⁻¹. Dexmedetomidine infusion was continued for 20 min throughout the procedure. Mean values of monitoring data of the patient were recorded as peripheral oxygen saturation: 98% (range 96–99), heart rate: 138 beats/min (range 130–171), respiratory rate: 26/min (range 23–30) (Fig. 1). During the process, Ramsey Sedation Score was found 4. Dexmedetomidine infusion was terminated at the end of operation and patient follow-up was continued in the postanesthesia care unit. Patient was sent to service after the full awakens and the patient was discharged on the same day.

There was no need an application such as mask ventilation, laryngoscopy, intubation and laryngeal mask in this case with difficult airway. It has been reported the use of dexmedetomidine has provide adequate sedation without respiratory depression.⁴

Because of these beneficial effects, we approved the administration of dexmedetomidine to 65 days aged infant and diagnosed KFS patient. Sedation is important in such cases which is considered limited neck

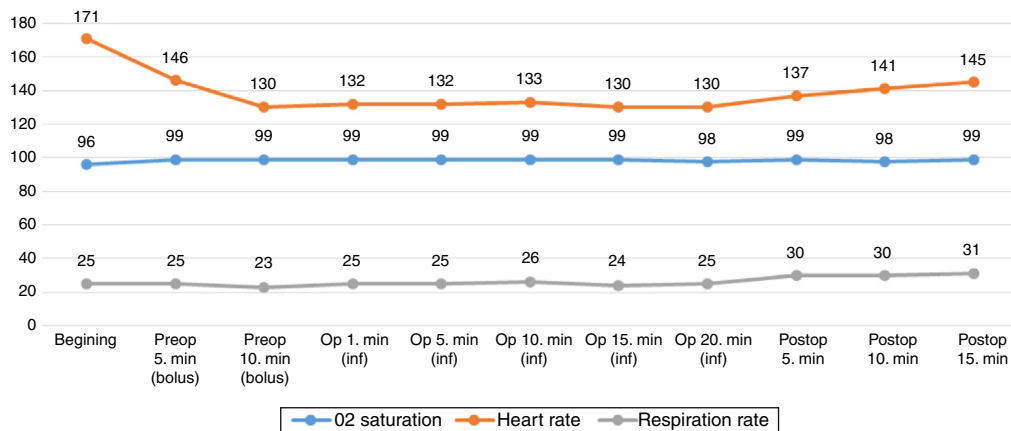


Figure 1 Monitorization data.

motions and difficult airway. We believe that dexmedetomidine is an agent may be preferred an alternative agent ensuring respiratory control in anesthesia procedures for sedation.

Conflicts interest

The authors declare no conflicts of interest.

References

1. Manivel S, Prasad R, Jacob R. Anesthetic management of a child with Klippel-Feil syndrome in the radiology suite. *Paediatr Anaesth.* 2005;15:171–2.
2. Cakmakkaya OS, Kaya G, Altintas F, et al. Anesthetic management of a child with Arnold-Chiari malformation and Klippel-Feil syndrome. *Paediatr Anaesth.* 2006;16:355–6.
3. Subramanyam R, Cudilo EM, Hossain MM, et al. To pretreat or not to pretreat: prophylactic anticholinergic administration before dexmedetomidine in pediatric imaging. *Anesth Analg.* 2015;121:479–85.

4. Shah TH, Badve MS, Olajide KO, et al. Dexmedetomidine for an awake fiber-optic intubation of a parturient with Klippel-Feil syndrome. Type I Arnold Chiari malformation and status post released tethered spinal cord presenting for repeat cesarean section. *Clin Pract.* 2011;1:57.

Ahmet Selim Ozkan*, Sedat Akbas, Mehmet Ali Erdogan, Ramazan Kirteke, Mahmut Durmus

Turgut Ozal Medicine Center, Department of Anesthesia, Malatya, Turkey

* Corresponding author.

E-mail: asozkan61@yahoo.com (A.S. Ozkan).

Available online 10 May 2016

<http://dx.doi.org/10.1016/j.bjane.2016.02.001>
0104-0014/

© 2016 Sociedade Brasileira de Anestesiologia. Published by Elsevier Editora Ltda. This is an open access article under the CC BY-NC-ND license (<http://creativecommons.org/licenses/by-nc-nd/4.0/>).

Cardiac arrest animal model: a simple device for small animals' chest compression



Modelo animal de parada cardíaca: um dispositivo simples para a compressão torácica em pequenos animais

Dear Editor,

Based on the poor outcome of Cardiac Arrest (CA), many animal models have been proposed to better understand the pathophysiology of this event. Animal models have also been used to understand the effects of Cardiopulmonary Resuscitation (CPR) in patients with CA. However, development of CA models is difficult, especially when dealing with small animals. Small animals are more economic compared to large animal, but they have far more complex instrumentation, poor survival, monitoring difficulties and some specific purposes devices are not available.

One of the main difficulties, especially when dealing with CA for small animals, is the chest compression. Most of the studies use either manual or expensive designed machines for chest compressions.^{1,2} The main problem with manual chest compression is the lack of consistency of the CPR, resulting in differences of the chest compression (i.e. depth and frequency), fatigue of the CPR performer, and possible internal organ damage from over compression. Thus, the use of a mechanical device is highly desirable for a great consistency. However, there is not a machine available that is designed for this purpose, then adaptations or development of new machines are necessary. Gazmuri et al. developed a custom-made pneumatic chest compression that allows for frequency and depth regulation.¹ The main problem with this machine is the price, as it needs to be customized parts.

One solution that our lab has adopted recently was the use of a modified sewing machine that was able to provide mechanical chest compression with low cost. The machine had all sewing-related parts removed (throat plate, bobbin housing, loop taker and bed shafts) and a speed controller substituted the pedal (Fig. 1). The presser foot was removed and the needle bar was cut. A small pistol head was fitter to the needle bar in order to adequately compress the heart. These modifications allowed good chest compression and rate control. By removing the bobbin housing, the animal could be fitted under the piston for chest compression. The depth of the chest compression could be adjusted by the height of table which the animal is laying.

In order to test the machine, seven male Wistar rats (300 g) were submitted to femoral artery and right external jugular vein cannulation. After cannulation, the right ventricle was stimulated with 1 mA at 60 Hz to induce and ventricular fibrillation. The stimulation was kept for 3 minutes in order to prevent spontaneous defibrillation. The CA was also noted by the absence of arterial blood pressure on the monitor. After five minutes of CA, the machine was turned on to a rate of 200 chest compressions per minute, a dose of 20 mcg/kg of epinephrine was injected and a diastolic blood pressure greater than 20 mmHg was aimed. The chest compressions depth was calculated to maintain one third of the antero-posterior chest diameter. In order to minimize possible intrathoracic organ lesion, the depth of chest compression was kept to less than 17 mm.¹ With three minutes of chest compressions, the rhythm was checked and if ventricular fibrillation or ventricular tachycardia was present, biphasic defibrillation with 7J was performed and CPR was promptly returned. With 6 minutes of CPR, the rhythm was rechecked and defibrillation with 7J was performed if ventricular fibrillation or ventricular tachycardia was present. Every 3 minutes, epinephrine was repeated until Return of Spontaneous Circulation (ROSC).